

**The impact of pathology, type of resection, and age at  
surgery on the postoperative seizure and  
cognitive outcome in patients with  
temporal lobe epilepsy**

Doctoral thesis  
to obtain a doctorate (PhD)  
from the Faculty of Medicine  
of the University of Bonn

**Julia Taube**  
from Prenzlau, Germany  
2023

Written with authorization of  
the Faculty of Medicine of the University of Bonn

First reviewer: Prof. Dr. phil. Christoph Helmstaedter

Second reviewer: Prof. Dr. Dr. Rene Hurlemann

Day of oral examination: 5 May 2023

For the Department of Epileptology

Director: Prof. Dr. Rainer Surges

## **Dedication**

Mit besonderem Dank und großer Liebe widme ich diese Arbeit meiner Schwester Claudia und meiner Mama Gabriele, die mich immer wieder inspirieren.

## Table of Contents

List of abbreviations	5
1 Abstract	6
2 Introduction and aims	8
2.1 Temporal Lobe Epilepsy and Cognition	8
2.2 Temporal Lobe Surgery and Cognition	10
2.3 Aims	11
2.3.1 Gliosis only (GO) and hippocampal sclerosis (HS)	11
2.3.2 Targeting epileptic networks by resection of piriform cortex	12
2.3.3 Epilepsy surgery in late adulthood	12
3 Publications	14
3.1 Publication 1: Resective temporal lobe surgery in refractory temporal lobe epilepsy: prognostic factors of postoperative seizure outcome	14
3.2 Publication 2: 'Hippocampal innate inflammatory gliosis only' in pharmaco-resistant temporal lobe epilepsy	25
3.3 Publication 3: Preoperative and postoperative memory in epilepsy patients with 'gliosis only' versus hippocampal sclerosis: a matched case-control study	38
3.4 Publication 4: Resection of piriform cortex predicts seizure freedom in temporal lobe epilepsy	46
3.5 Publication 5: Surgery for temporal lobe epilepsy in the elderly: Improving quality of life despite cognitive impairment	60
4 Discussion	69
4.1 Summary and outlook	69
4.2 Conclusion	72
5 References	74
6 Acknowledgements	83
7 Publications	84

**List of abbreviations**

ASM	Anti-seizure medication
ATL	Anterior Temporal Lobectomy
GO	Gliosis only without hippocampal sclerosis
HS	Hippocampal Sclerosis
MRI	Magnetic resonance imaging
PIC	Piriform Cortex
PWE	People with epilepsy
sAHE	Selective amygdalohippocampectomy
TL	Temporal lobe
TLE	Temporal lobe epilepsy
TLS	Temporal lobe surgery

## 1 Abstract

In this thesis, epilepsy- and surgery-related factors were investigated for their effects on postoperative seizure and cognitive outcome in patients with medically intractable temporal lobe epilepsy (TLE).

As a first step, Borger, Hamed, Taube, et al. (2021) evaluated various clinical factors contributing to an (un-)favorable surgical outcome in a large consecutive cohort. While seizure freedom rates and cognitive changes were comparable to those of the previously reported cohorts, this was the first study to identify the histopathological diagnosis of 'no hippocampal sclerosis with gliosis only' (GO) as a risk factor for seizure recurrence after surgery. This questions the current assumption that GO is a predecessor of the histopathological diagnosis of 'hippocampal sclerosis' (HS). Hence, Grote, Heiland, Taube, et al. (2022) and Taube, et al. (2022) investigated differences between GO and HS further. The later epilepsy onset, higher surgical failure rates, mild memory impairments before surgery, and greater postoperative memory losses favor the hypothesis that GO represents a distinct clinical entity. Moreover, we found evidence of transcriptomic dysregulation in GO suggestive of inflammatory processes through activation of the complement system. Our results question not only the current clinical practice in treating patients with TLE due to GO, but also emphasize the need for an investigation of inflammatory mediators at the onset of TLE.

The involvement of spatiotemporal networks in the epileptic brain exceeding the lesional epileptogenic zone (EZ) is increasingly well recognized. This has significant implications for optimal resection extent because surgically targeting these epileptic circuits may result in improved seizure outcomes. Borger, Schneider, Taube, et al. (2021) retrospectively evaluated the impact of surgically removing the piriform cortex (PIC), considered a hub for generating and spreading seizures, on postoperative outcomes. Seizure outcomes improved with larger PIC resection extent, while the risk of complications and adverse neuropsychological events did not increase. Future studies need to assess the surgical amenability of the PIC and

identify how residual involved cortical and subcortical circuits contribute to surgical failures in the treatment of focal epilepsies.

The fifth study by Delev, Taube, et. al (2020) assessed the safety and efficacy of temporal lobe surgery (TLS) in late adulthood. While TLE has been linked to accelerated brain aging, the effects of TLS are inconclusive. Since seizures were controlled in the majority of our patients, TLS can counteract the contribution of epileptic dysfunction, injuries during seizures, and high drug load to cognitive impairments. The cognitive costs of TLS were comparable to those reported in younger cohorts despite evidence of more severe memory impairments already before surgery. Even though long-term outcome studies indicate no progressive memory decline beyond the immediate postoperative losses, TLS in late adulthood may nonetheless contribute to reaching a disabling level of extensive memory impairment much earlier. Especially in the light of accumulating evidence that epileptogenesis and neurodegeneration share common etiological mechanisms, patients most at risk of severe cognitive sequelae following epilepsy surgery must be identified via early investigation of cerebrospinal fluid and neuroimaging biomarkers.

The present thesis contributes to our understanding of the impact of clinical and etiological factors on postoperative cognitive and seizure outcomes. The results emphasize the importance of pathology-dependent surgical counseling and decision-making to improve individual medical care.

## 2 Introduction and aims

Temporal lobe epilepsy (TLE) is a common neurological condition characterized by recurrent disabling seizures and major cognitive sequelae resulting from morphological changes in the hippocampus, the amygdala, or the lateral temporal lobe (TL). Approximately 30% of people with epilepsy (PWE) continue to suffer from seizures despite taking appropriate anti-seizure medication (ASM), which puts them at risk of increased morbidity, mortality, adverse cognitive and psychosocial consequences as well as accelerated brain ageing (de Bézenac et al., 2021; Fisher et al., 2014; Kwan et al., 2010; Puka, Tavares, & Speechley, 2019; Tellez-Zenteno et al., 2007). If the epileptogenic brain tissue is localizable and surgically amenable without causing disabling cognitive or other neurological sequelae, epilepsy surgery remains the only available curative treatment (Engel et al., 2003; Jobst & Cascino, 2015; Wiebe et al., 2001). Therefore, neuropsychological assessments are integral in the clinical evaluation of patients considered for surgery. The postoperative examination is essential for outcome and quality control seeking to improve individual medical care (Helmstaedter, 2004; Loring, 1997; Trenerry, 1996). Maintaining cognitive abilities and preventing cognitive decline in PWE challenges epileptologists and neurosurgeons alike (Borger et al., 2021a; Helmstaedter, 2004; Vogt et al., 2017; Witt & Helmstaedter, 2009).

### 2.1 Temporal Lobe Epilepsy and Cognition

Cognitive problems are major comorbidities of epilepsy (Helmstaedter & Witt, 2012; Witt & Helmstaedter, 2015). A significant number of patients (~50%) already suffer from cognitive impairment at disease onset (Witt & Helmstaedter, 2012). Cognition often worsens over time depending on the contribution of many epilepsy-related factors, i.e., the etiology (e.g., developmental lesions, sclerosis, inflammation), the localization/lateralization (e.g. temporal, frontal, left or right hemisphere), the degree of epileptic dysfunction (e.g. seizures, interictal activity), and



treatment effects, e.g., ASM or surgery (Helmstaedter & Witt, 2017; Mula, Coleman, & Wilson, 2022).

The clinical preconditions determine the cognitive profile of patients with effects on attention, executive functions, memory, language, visuospatial abilities, and intelligence (Helmstaedter & Witt, 2012; Helmstaedter, Kemper, & Elger, 1996; McDonald et al., 2022). TLE is associated with impaired episodic memory as the most common cognitive impairment (Chelune, 1995; Moscovitch et al., 2016; Scoville & Milner, 1957). This has been investigated primarily in patients with ‘hippocampal sclerosis’ (HS), long recognized as the most prevalent brain lesion causing TLE. The histopathological hallmark of HS is significant neuronal cell loss and reactive astrogliosis leading to hippocampal atrophy (Blumcke, Cross, & Spreafico, 2013).

According to the ‘hippocampal adequacy model’, the degree of memory impairment depends on the structural integrity or the overall pathological status of the hippocampus (Chelune, 1995). In support of this notion, previous studies reported more severe memory impairments in patients with a more severe loss of hippocampal cell densities and hippocampal volume (Trenerry, Westerveld, & Meador, 1995; Witt et al., 2014a; Zentner et al., 1999). Moreover, impairments in learning and memory tend to be material-specific depending on the lateralization of TLE. While left TLE is associated with verbal memory impairment, right TLE is linked to visual (non-verbal) memory impairment (Gargaro et al., 2013; Gleissner, Helmstaedter, & Elger, 1998; Helmstaedter et al., 1997, 2008; Saling, 2009; Zannino et al., 2020).

Additionally, individual reserve capacities are essential in modulating cognitive impairments pre- and postoperatively (Chelune, 1995). Support for the ‘hippocampal reserve model’ comes from early observations of severe memory impairments following unilateral TLS producing the functional equivalent of bilateral hippocampal resections (Scoville & Milner, 1957). Postmortem histopathological analyses identified contralateral pathological hippocampal changes in these patients as well. Therefore, it was hypothesized that the structural and functional integrity of the contralateral hippocampus was essential for supporting memory postoperatively.

## 2.2 Temporal Lobe Surgery and Cognition

For PWE with uncontrolled seizures, epilepsy surgery is generally a safe and effective treatment option, despite the cognitive costs (Engel, 2018). The presurgical evaluation comprises a comprehensive multi-disciplinary assessment of seizure semiology, (non)-invasive electrophysiological monitoring, epilepsy-specific MRI protocols, functional imaging (Positron emission tomography, single photon emission computed tomography), and a neuropsychological assessment. Thereby, each patient can be provided with a risk and benefit assessment of the possible postoperative seizure and cognitive outcome (Helmstaedter, 2004).

A large cohort study reported that the long-term seizure outcome was favorable for 66% of patients, even though results varied between 51% and 75% depending on the localization and lateralization, pathology, surgical approach, and resection extent, as well as the duration of epilepsy, and types of seizures (Jobst & Cascino, 2015; Lamberink et al., 2020). While seizure outcome has been comparable between standard temporal lobe resections, e.g., anterior temporal lobectomy (ATL), and strictly mesial resections, e.g., transsylvian selective amygdalohippocampectomy (sAHE), the neuropsychological outcome tends to be better following more selective approaches (Clusmann et al., 2002; Gleissner et al., 2004; Helmstaedter et al., 2004; Lutz et al., 2004; Schramm, 2008; Tanriverdi et al., 2008). However, the optimal extent of resection for the best seizure outcome remains controversial (Schramm, 2008).

In addition to seizure control, adverse cognitive effects of surgery are significant factors in deciding whether epilepsy surgery can be considered a success or a failure for the individual patient (Cook & Baxendale, 2022; Lunney et al., 2018). The postoperative cognitive changes are primarily determined by (i) the side of surgery (language dominant vs. non-dominant hemisphere) and (ii) the preoperative functional status (Bell et al., 2009; Helmstaedter, 2004; Trenerry et al., 1995; Vogt et al., 2014). A lack of impairment or mild impairment is associated with a greater postoperative memory decline (Helmstaedter, Petzold, & Bien, 2011; Hermann et al., 1992). Previous research showed that decrements in verbal memory were evident in 40-50% of the patients after left TLS and 20-30% after right TLS, whereas

visual memory declined in about 20-30% of patients without a lateralization effect (Helmstaedter, 2013; Sherman et al., 2011).

Predicting TLS outcomes remains challenging. Therefore, this doctoral thesis aimed to investigate clinical and etiological factors contributing to a good seizure and cognitive outcome as they provide the basis for evidence-based decision-making in the treatment of PWE.

## 2.3 Aims

Accordingly, the first study by Borger, Hamed, Taube, et al. (2021) was conducted to investigate predictors of postoperative seizure and cognitive outcome in a large consecutive cohort of TLE patients who underwent resective TLS. In this study, clinical, neuropsychological, and histopathological data were retrospectively analyzed to assess their impact on the treatment outcome. The histopathological diagnosis of 'no hippocampal sclerosis, gliosis only' (GO) was identified as a major risk factor for poor seizure outcome. Therefore, the following studies by Grote, Heiland, Taube, et al. (2022) and Taube, et al. (2022) and explored the clinical, neuropsychological, and histopathological characteristics of patients with GO in a large retrospective cohort and compared the results to patients with HS.

### 2.3.1 Gliosis only (GO) and hippocampal sclerosis (HS)

Gliosis only has long been recognized as a predecessor of HS, since its histopathological hallmark constitutes reactive astrocytes without extensive neuronal cell loss. However, considering higher surgical failure rates, this assumption needs to be questioned since previous studies found evidence for an association of earlier treatment and improved seizure outcomes (Langfitt & Wiebe, 2008). Hippocampal sclerosis and GO share pathological mechanisms contributing to epileptogenesis characterized by a complex network dysfunction between neurons and glia. Moreover, astrocytic dysfunction, as the main finding in GO, is additionally associated with changes in the activation and clearance of the complement immune system triggering inflammation (Farina, Aloisi, & Meinl, 2007). Based on these precedents, different pathomechanisms contributing to epileptogenesis in GO and HS can be suspected.

Additional evidence from brain imaging suggests a bilateral hippocampal affection in GO but not in HS, even though unilateral TLE was suspected (Hattingen et al., 2018). Thus, we propose that differences between HS and GO should become evident at a functional level before surgery. Inflammatory involvement, high surgical failure rates, and bilateral hippocampal pathology, even though structurally more intact, in patients with GO put these patients at an increased risk of cognitive decline after surgery. Thus, our study results may argue for an important reconsideration of future diagnostic and surgical practice during the treatment.

### 2.3.2 Targeting epileptic networks by resection of piriform cortex

It is increasingly recognized that epilepsy resembles a network disease. Hence, seizures that continue after surgery likely result from residual epileptic circuits insufficiently interrupted by the resection. The piriform cortex (PIC) is thought to be an important node of epileptic networks in focal epilepsy because it has broad connections to the limbic and cortical areas (Chee et al., 2022; Young et al., 2019). Cumulative evidence from animal studies suggests that it is highly vulnerable to excitotoxicity, thereby contributing to epileptogenesis (Cheng et al., 2020; Koepp & Galovic, 2020). Hence, it has been discussed as a therapeutic target for treating refractory TLE (Koubeissi, 2020; Vaughan & Jackson, 2014). The fourth study by Borger, Schneider, Taube, et al. (2021) assessed whether (PIC) resection in TLE would improve postoperative outcomes after selective surgery without increasing the risk of complications and higher cognitive costs.

### 2.3.3 Epilepsy surgery in late adulthood

Treating elderly PWE is a unique challenge because of multiple comorbidities, physiologic changes, and adverse treatment effects through polypharmaco-therapy (Gallo, 2006; Perucca et al., 2006). Moreover, cognitive deficits are generally more severe, especially in memory, attention, and executive functions (Witt et al., 2014b). These deficits are likely to progress, which occurs as part of natural brain aging but also because of epilepsy- and treatment- related factors (de Bézenac et al., 2021; Helmstaedter et al., 2003). Therefore, being affected by epilepsy

in late adulthood is associated with a higher risk of reaching critical thresholds for significant functional impairment earlier (Sen, Capelli, & Husain, 2018).

Epilepsy surgery is underutilized in these patients because of concerns regarding a less favorable seizure outcome, and more perioperative complications (Grivas et al., 2006). While the question whether epilepsy surgery further adds to a progressive cognitive decline remains unanswered, at the same time postoperative seizure-freedom may counteract the contribution of epileptic dysfunction, injuries during seizures and high drug load to cognitive impairments. Considering emerging evidence that epilepsy and dementia share common pathomechanisms, detection of comorbid neurodegeneration or risk of such is of utmost importance when an elderly patient is considered for surgery (Sen et al., 2018).

Only few studies have addressed the postoperative outcome in elderly patients after epilepsy surgery, and heterogeneous patient cohorts, small sample sizes, and short-term follow-ups limit the validity of risk and benefit assessments before surgery. This study comprised a homogenous sample of patients above 50 years of age who underwent TLS for treating TLE due to HS. Delev, Taube, et. al (2020) assessed whether TLS in elderly patients is a safe and effective treatment option.

### **3 Publications**

- 3.1 Publication 1: Resective temporal lobe surgery in refractory temporal lobe epilepsy: prognostic factors of postoperative seizure outcome

## Resective temporal lobe surgery in refractory temporal lobe epilepsy: prognostic factors of postoperative seizure outcome

Valeri Borger, MD,<sup>1</sup> Motaz Hamed, MD,<sup>1</sup> Julia Taube, MSc,<sup>2</sup> Gülsah Aydin, MD,<sup>1</sup> Inja Ilic, MD,<sup>1</sup> Matthias Schneider, MD,<sup>1</sup> Patrick Schuss, MD, PhD,<sup>1</sup> Erdem Güresir, MD, PhD,<sup>1</sup> Albert Becker, MD, PhD,<sup>3</sup> Christoph Helmstaedter, PhD,<sup>2</sup> Christian E. Elger, MD, PhD,<sup>2</sup> and Hartmut Vatter, MD, PhD<sup>1</sup>

Departments of <sup>1</sup>Neurosurgery and <sup>2</sup>Epileptology, and <sup>3</sup>Institute of Neuropathology, University Hospital Bonn, Germany

**OBJECTIVE** Temporal lobe epilepsy (TLE) is one of the most common forms of epilepsy. In approximately 30% of patients, seizures are refractory to drug treatment. Despite the achievements of modern presurgical evaluation in recent years, the presurgical prediction of seizure outcome remains difficult. The aim of this study was to evaluate the seizure outcome in patients with drug-refractory TLE who underwent resective temporal lobe surgery (rTLS) and to determine features associated with unfavorable postsurgical seizure outcome.

**METHODS** Patients with medically refractory TLE who underwent rTLS between 2012 and 2017 were reviewed from the prospectively collected epilepsy surgery database. A retrospective analysis of clinical, radiological, neuropsychological, histopathological, and perioperative findings of 161 patients was performed. The patients were divided into two groups according to seizure outcome (group I, International League Against Epilepsy [ILAE] class 1; group II, ILAE class  $\geq$  2). For identification of independent risk factors for unfavorable postoperative seizure outcome (ILAE class  $\geq$  2), a multivariate logistic regression analysis was performed.

**RESULTS** Seizure freedom (ILAE class 1) was achieved in 121 patients (75.2%). The neuropsychological evaluation demonstrated that losses in cognitive performance were more pronounced in verbal memory after resections in the left temporal lobe and in nonverbal memory after right-sided resections, whereas attention improved after surgery. Overall, postoperative visual field deficits (VFDs) were common and occurred in 51% of patients. There was no statistically significant difference in the incidence of VFD in patients with selective surgical procedures compared to the patients with nonselective procedures. The lack of MRI lesions and placement of depth electrodes were preoperatively identified as predictors for unfavorable seizure outcome.

**CONCLUSIONS** rTLS is an effective treatment method in patients with refractory TLE. However, patients with a lack of MRI lesions and placement of depth electrodes prior to rTLS are at higher risk for an unfavorable postsurgical seizure outcome.

<https://thejns.org/doi/abs/10.3171/2020.7.JNS20284>

**KEYWORDS** epilepsy surgery; hippocampal gliosis; temporal lobe epilepsy; seizure outcome

**T**EMPORAL lobe epilepsy (TLE) is one of the most common forms of epilepsy, first described by Hughlings-Jackson. In approximately 30% of patients, seizures are refractory to drug treatment.<sup>1</sup> Since the first randomized controlled trial by Wiebe et al. showed significantly improved outcomes with epilepsy surgery over drug treatment in refractory TLE, resective tempo-

ral lobe surgery (rTLS) has been a reasonable option for treatment in these patients.<sup>2</sup> In a meta-analysis including 32 studies with 2250 patients, Engel et al. reported that after rTLS, seizure freedom was achieved in 65% of patients with TLE.<sup>3</sup> In a recently published review, Englot and Chang reported that the existing data favoring surgery for appropriately selected candidates with refractory

**ABBREVIATIONS** AHE = amygdalohippocampectomy; ATL = anterior temporal lobectomy; CA = cornu ammonis; CI = confidence interval; DCS-R = Diagnostikum für Zerebralschäden–Revised; EEG = electroencephalography; FCD = focal cortical dysplasia; HG = hippocampal gliosis; HS = hippocampal sclerosis; ILAE = International League Against Epilepsy; OR = odds ratio; rTLS = resective temporal lobe surgery; sAHE = selective AHE; TLE = temporal lobe epilepsy; VFD = visual field deficit; VLMT = verbal learning and memory test.

**SUBMITTED** January 29, 2020. **ACCEPTED** July 31, 2020.

**INCLUDE WHEN CITING** Published online January 8, 2021; DOI: 10.3171/2020.7.JNS20284.

TLE are convincing and suggest that a cure is possible in some patients with this disorder.<sup>4</sup> Despite this fact and all achievements of modern presurgical evaluation in recent years, the presurgical prediction of seizure outcome remains difficult. The aim of this study was to evaluate seizure outcome in patients with drug-refractory TLE who underwent rTLS at our center and to determine features associated with unfavorable postsurgical seizure outcome.

## Methods

### Population and Presurgical Evaluation

Patients with TLE who underwent rTLS between 2012 and 2017 were reviewed from the prospectively conducted epilepsy surgery database at our center. The formation of this database was approved by the local ethics committee. Given the retrospective nature of the study, written informed consent was not required.

During the studied period, rTLS was performed in a total of 184 patients. There were 23 cases lost to follow-up; the most common reason was treatment of patients from abroad who moved back to their countries after surgery. These patients did not complete the follow-up visits at our center. Because we included only patients with completed follow-up at 12 months after rTLS, complete data sets for 161 consecutive patients were available. All patients suffered from medically refractory TLE and had undergone adequate treatment with at least two first-line antiepileptic drugs. A retrospective analysis of clinical, radiological, histopathological, and perioperative findings was performed.

All patients were preoperatively assessed in the department of epileptology in a similar fashion and were considered to be suitable for surgery.<sup>5,6</sup> The evaluation included detailed history of seizures, medical history, high resolution 3-T MRI, neuropsychological assessment, and video-electroencephalography (EEG) monitoring using continuous recordings. In patients with absent or several lesions on MRI, PET and SPECT were performed to identify a seizure focus. In cases with inconclusive findings, invasive EEG monitoring was performed using stereotactically implanted depth electrodes.<sup>7</sup>

### Surgical Procedures

All surgical procedures were performed while patients were under general anesthesia using intraoperative neuronavigation and intraoperative neurophysiological monitoring with motor evoked and somatosensory evoked potentials. The goal of surgery was to remove temporal and temporomesial structures, including the lesion depicted on MRI or anatomical area with presumed seizure focus.

### Histopathological Examination

The resected tissue was obtained from all patients in this study. Standardized neuropathological analysis was performed in all preserved specimens by local neuropathologists. The histopathological findings were differentiated into three categories. First were hippocampal pathologies such as hippocampal sclerosis (HS) or hippocampal gliosis (HG) according to the International League Against Epilepsy (ILAE) classification.<sup>8</sup> Next

were pathologies within the temporal lobe without the involvement of the hippocampus, such as gliosis, ganglioglioma, cavernoma, and focal cortical dysplasia (FCD). The diagnosis of HG was histologically confirmed as reactive astrogliosis without neuronal loss within the resected hippocampus. Neoplastic lesions were classified according to the WHO classification.<sup>9</sup> The FCD was classified according to the new ILAE classification.<sup>10</sup> The last category was no specific pathological changes.

### Surgical Outcome Analysis

After rTLS, the outcome was assessed during follow-up visits at 6 and 12 months. Patients with a follow-up period less than 12 months were not included in this study. At the 12-month visit, all patients underwent a thorough clinical examination, evaluation of seizure outcome, video-EEG recording, 3-T MRI, and neuropsychological reassessment. The postoperative seizure outcome was assessed according to the ILAE classification.<sup>11</sup> The patients were divided into two groups according to seizure outcome: group I (ILAE class 1) and group II (ILAE class  $\geq$  2).

Surgically associated complications were assessed during the postoperative course of treatment. The clinically relevant events requiring surgical revision, such as bleeding complications and surgical site infections, were analyzed. Furthermore, relevant newly occurring neurological deficits such as motor deficits, aphasia, and cranial nerve palsies were assessed and analyzed.

All patients underwent MRI within 2–3 days postoperatively to detect the extent of resection of desired structures. Incomplete resection was determined in cases in which a substantial remnant of target tissue was not reached by resection as confirmed by postoperative MRI, whether it was from imprecise delimitation or surgical and functional limitation. The target structures were different according to the surgical procedure. In candidates who underwent selective amygdalohippocampectomy (sAHE) or anterior temporal lobectomy (ATL) with amygdalohippocampectomy (ATL with AHE), the resection was stated as incomplete if mesial temporal structures such as the hippocampus, amygdala, or superior part of the uncus were insufficiently removed. In patients who underwent temporal lesionectomy or ATL without AHE, the resection was incomplete if any parts of the epileptogenic lesion were not addressed by the surgery. After completion of the presurgical evaluation, the extent of resection and the desired structures that were intended to be removed were defined by the responsible epileptologist and reviewed by the interdisciplinary epilepsy surgery conference. In cases where needed, resection masks were generated and included in the intraoperative neuronavigation. Following surgery, the resection was matched with the presurgical resection mask to confirm the proper extent of resection. The postoperative MRI was performed in each patient within 2–3 days to confirm the extent of resection of addressed structures or lesions and rule out surgical complications such as bleeding, infarction, and damage to brain tissue along the surgical approach. The postsurgical MR images were analyzed by experienced neuroradiologists.



## Neuropsychological Assessment

The neuropsychological evaluation focused on tests of verbal and nonverbal memory representing temporal lobe functions. In addition, attention and executive functions, visuospatial abilities, and language and motor functions were considered. Verbal memory was measured via the verbal learning and memory test (VLMT). For visual learning, the Diagnostikum für Zerebralschäden–Revised (DCS-R) was applied. Parallel versions of the VLMT and DCS-R were used to minimize practice effects at the follow-up. Attention was assessed by the EpiTrack screening tool and the d2 Aufmerksamkeitsbelastungstest. Language assessment comprised the BNT and the Token Test. Visuospatial abilities were evaluated via Leistungsprüfungssystem substest 7 and Wechsler Adult Intelligence Scale block design. The tests and their references are described in previous articles.<sup>12</sup> Pre- and postoperative test results from each cognitive domain were summarized and classified into a 5-point scale, ranging from severely impaired to above average (severely impaired = 0, at least two test scores > 2 standard deviations below the mean of the normative sample; impaired = 1, at least two test scores > 1 standard deviation below the mean; borderline = 2, one test score below the mean; unimpaired = 3, no test score > 1 standard deviation below the mean; above average = 4, at least two test scores > 1 standard deviation above the mean). The distance between two subsequent categories approximately corresponds to one standard deviation from the mean standardized score across all test scores of the respective domain.

## Ophthalmological Examination

Visual fields were examined in each patient pre- and postoperatively using kinetic Goldmann perimetry. A new postoperatively diagnosed visual field deficit (VFD) was classified as a superior quadrantanopia or homonymous hemianopia.

## Statistical Analysis

Statistical data analysis was performed using the SPSS software package (IBM SPSS Statistics for Windows, version 25.0., IBM Corp.). Associations between parametric variables were analyzed using an unpaired, two-tailed Student t-test. For analysis of associations between non-parametric variables, the Mann-Whitney U-test was used. Associations of categorical variables were compared using the chi-square or Fisher exact test. Results with *p* values < 0.05 were considered statistically significant. For identification of independent risk factors for unfavorable postoperative seizure outcome (ILAE class ≥ 2), a multivariate logistic regression analysis was performed including the variables with significant *p* values in univariate analysis. The results of the analysis were presented by logistic regression as odds ratio (OR) with a 95% confidence interval (CI).

## Results

### Population and Presurgical Evaluation

In total, data from 161 patients who underwent rTLS

for TLE were included in this analysis. There were 85 males (52.8%). The surgery was performed in 81 patients (50.3%) on the left side and in 80 (49.7%) on the right. The mean age at epilepsy onset was  $17.32 \pm 13.09$  years, and the mean age at surgery was  $36.1 \pm 14.96$  years. The mean duration of epilepsy was  $19.1 \pm 13.77$  years. According to seizure outcome, 121 patients were assigned to group I (ILAE class 1) and 40 to group II (ILAE class ≥ 2). Regarding basic clinical characteristics such as age at seizure onset, age at surgery, duration of epilepsy, and side of surgery, there were no statistically significant differences (Table 1). During the presurgical evaluation, the invasive evaluation using depth electrodes was performed in significantly more patients in group II compared to group I (15 [37.5%] vs 21 [17.4%], *p* = 0.015). The analysis of preoperative MRI revealed the evidence of HS as the most common radiological pathology in both groups (79 [65.3%] in group I vs 20 [50.0%] in group II, nonsignificant difference). The distribution of other lesions is shown in Table 1. A negative MR image without any lesions was found significantly more often in group II compared with group I (8 [20%] vs 6 [5%], *p* = 0.007).

## Surgical Procedures

Overall, the leading surgical procedure performed was transylvian sAHE in 91 of 161 patients. The ATL with AHE was performed in 30 of 161 patients and without AHE in 15 of 161 patients. In 20 of 161 patients, a tailored lesionectomy without AHE was performed followed by lesionectomy with AHE in 5 of 161 patients. As shown in Table 2, the analysis revealed no differences related to surgical procedure between the two outcome groups.

## Histopathological Examination

The overview of the histopathological findings is shown in Table 1. There were significantly more patients with HS in the group with favorable seizure outcome (77 [63.6%] in group I vs 17 [42.5%] in group II, *p* = 0.026). Furthermore, the prevalence of HG was significantly higher in group II compared with group I (11 [27.5%] vs 10 [8.3%], *p* = 0.05). In regard to other histopathological findings, the groups did not differ significantly (Table 1).

## Surgical Outcome Analysis

Of the 161 patients, at 6- and 12-month follow-up visits after rTLS a favorable seizure outcome with seizure freedom (ILAE class 1) was achieved in 121 patients (75.2%). The proportion of patients with ILAE class 2–6 was not significantly different for each ILAE class at the 6- and 12-month follow-ups, respectively (Table 3). The analysis of surgical complications revealed an overall complication rate of 11.8%. The overall rate of revision surgery was 8.1% (Table 2). Surgical site infections were the most frequent complication (in 9 [5.6%] of 161 patients), followed by bleeding complications (6 [3.7%] of 161 patients). The comparison of the two outcome groups revealed no significant differences, either for overall complication rate or rate of surgical revision, or for bleeding complications and infections in each group (Table 2). Transient motor neurological deficits such as paresis and hemiparesis occurred

**TABLE 1. Patient demographics and characteristics according to ILAE seizure outcome class**

Characteristic	Overall	Group I (ILAE class 1)	Group II (ILAE class 2–6)	p Value
No. of patients	161	121	40	
Sex, n (%)				
Male	85 (52.8)	62 (51.2)	23 (57.5)	NS
Female	76 (47.2)	59 (48.8)	17 (42.5)	NS
Mean age at epilepsy onset $\pm$ SD, yrs	17.32 $\pm$ 13.09	17.9 $\pm$ 13.59	15.56 $\pm$ 11.4	NS
Mean duration of epilepsy $\pm$ SD, yrs	19.1 $\pm$ 13.77	19.06 $\pm$ 13.8	19.4 $\pm$ 13.71	NS
Mean age at surgery $\pm$ SD, yrs	36.1 $\pm$ 14.96	36.66 $\pm$ 15.53	34.58 $\pm$ 13.12	NS
Site of surgery, n (%)				NS
Lt	81 (50.3)	56 (46.3)	25 (62.5)	NS
Rt	80 (49.7)	65 (53.7)	15 (37.5)	NS
Invasive presurgical evaluation w/ depth electrodes, n (%)	36 (22.4)	21 (17.4)	15 (37.5)	0.015
Preop MRI findings, n (%)				
Unilateral HS	99 (61.5)	79 (65.3)	20 (50.0)	NS
Hippocampal lesions other than HS	27 (16.8)	20 (16.5)	7 (17.5)	NS
Temporal lesion w/o hippocampal involvement	21 (13.0)	16 (13.2)	5 (12.5)	NS
No lesion	14 (8.7)	6 (5.0)	8 (20.0)	0.007
Histology of hippocampus, n (%)				
HS	94 (58.4)	77 (63.6)	17 (42.5)	0.026
HG	21 (13.0)	10 (8.3)	11 (27.5)	0.005
Histology of TL tissue w/o hippocampus, n (%)				
Temporal gliosis	11 (6.8)	6 (5.0)	5 (12.5)	NS
Ganglioglioma	9 (5.6)	7 (5.8)	2 (5.0)	NS
Cavernoma	6 (3.7)	5 (4.1)	1 (2.5)	NS
FCD type I	2 (1.2)	2 (1.7)	0 (0.0)	NS
Other	6 (3.7)	5 (4.1)	1 (2.5)	NS
No specific histopathological changes	12 (7.4)	9 (7.4)	3 (7.5)	NS

NS = nonsignificant; TL = temporal lobe.

in 8 (4.9%) of 161 patients and were not significantly different between groups I and II (6 [4.9%] vs 2 [5%], non-significant). The postoperative MRI showed that desired extent of resection was significantly often not achieved in group II compared to group I (4 [10%] in group II vs 2 [1.7%] in group I,  $p = 0.034$ ).

### Neuropsychological Outcome

Before surgery, visual memory was impaired in 66% of patients, followed by verbal memory, language, and attention in approximately 50% each. Visuospatial functions were affected in 39% of cases. Preoperatively, there were no significant differences in performance between left and right TLE ( $p = 0.29$ – $0.80$ ; Fig. 1).

Group-level analysis, by means of repeated-measures ANOVA, revealed an interaction effect of visual memory and surgical side ( $F [1,99] = 4.752$ ,  $p = 0.032$ ,  $\eta^2 = 0.046$ ). Patient performance was worse after right-sided resections (Fig. 2, left). A significant main effect of surgery ( $F [1,101] = 10.831$ ,  $p < 0.01$ ,  $\eta^2 = 0.097$ ) and a significant main effect of surgical side ( $F [1,101] = 4.379$ ,  $p < 0.05$ ,  $\eta^2 = 0.042$ ) were found for verbal memory. There was a trend for an interaction of side and surgery ( $F [1,101] = 3.127$ ,  $p = 0.08$ ,  $\eta^2 = 0.03$ ; Fig. 2, right). Attention significantly

improved after surgery ( $F [1, 99] = 12.561$ ,  $p < 0.01$ ,  $\eta^2 = 0.113$ ). Language and visuospatial abilities did not show significant changes.

Consistent with the group-level analysis, individual-level analysis indicated that verbal memory decline was more frequent after left rTLS (63%) than after right rTLS (38%). Visual memory was worse for 48% of the patients after right-sided and for 25% after left-sided resections ( $\chi^2 [6] = 11.373$ ,  $p < 0.05$ ). Deteriorations of visuospatial abilities and language were noted in 14%–19% of cases. Attention improved after surgery (39% vs 16%). Figure 3 displays the number of patients with significant individual changes, corrected for floor effects.

### Postoperative Visual Field Impairment

Overall, postoperative VFDs were common and occurred in 82 (51%) of 161 patients. The most frequent VFD was superior quadrantanopia (40%). Homonymous hemianopia occurred in 11% of the patients. There was no statistically significant difference in the overall incidence rate of VFD in patients with selective versus nonselective procedures, either for superior quadrantanopia or for homonymous hemianopia (Table 4).

**TABLE 2. Distribution of surgical modality and complications during the perioperative course of treatment according to seizure outcome**

Variable	Overall	Group I, n = 121	Group II, n = 40
<b>Surgery modality</b>			
sAHE	91 (56.5)	67 (55.4)	24 (60.0)
ATL w/ AHE	30 (18.6)	21 (17.3)	9 (22.5)
ATL w/o AHE	15 (9.3)	11 (9.1)	4 (10.0)
LE w/ AHE	5 (3.1)	4 (3.3)	1 (2.5)
LE only	20 (12.5)	18 (14.9)	2 (5.0)
<b>Overall surgical complications</b>			
Bleeding complication	6 (3.7)	4 (3.3)	2 (5.0)
Surgical site infection	9 (5.6)	5 (4.1)	4 (10.0)
Overall revision surgery	13 (8.1)	8 (6.6)	5 (12.5)

LE = lesionectomy.

Data are given as number (%). All statistical comparisons between the two groups for each variable were nonsignificant.

### Multivariate Logistic Regression Analysis

We performed a stepwise multivariate logistic regression analysis using the variables “invasive preoperative evaluation,” “evidence of a lesion in preoperative MRI,” “histopathological evidence of HS,” “histopathological evidence of HG,” and “extent of resection on postoperative MRI” to find independent predictors for unfavorable seizure outcome (ILAE class  $\geq 2$ ). The analysis showed that the histopathological evidence of HG (OR 4.99, 95% CI 1.9–13.1,  $p = 0.001$ ) and incomplete resection (OR 9.08, 95% CI 1.6–52.5,  $p = 0.014$ ) were independent and significant predictors for unfavorable seizure outcome after rTLS in TLE (Table 5).

### Discussion

Resective epilepsy surgery is an established treatment option in patients with focal refractory epilepsy, particularly those with TLE.<sup>2</sup> However, although it is effective, it has been demonstrated that seizure freedom rates decrease over time after surgery.<sup>13</sup> There are studies reporting that surgical treatment for TLE fails to provide a seizure-free outcome in 20%–30% of these patients.<sup>14,15</sup> The reasons behind failure of surgical treatment are multiple and comparison with existing data is difficult because of methodological issues. In this study, we tried to identify factors associated with unfavorable seizure outcome in patients with TLE who underwent rTLS. In the present study,

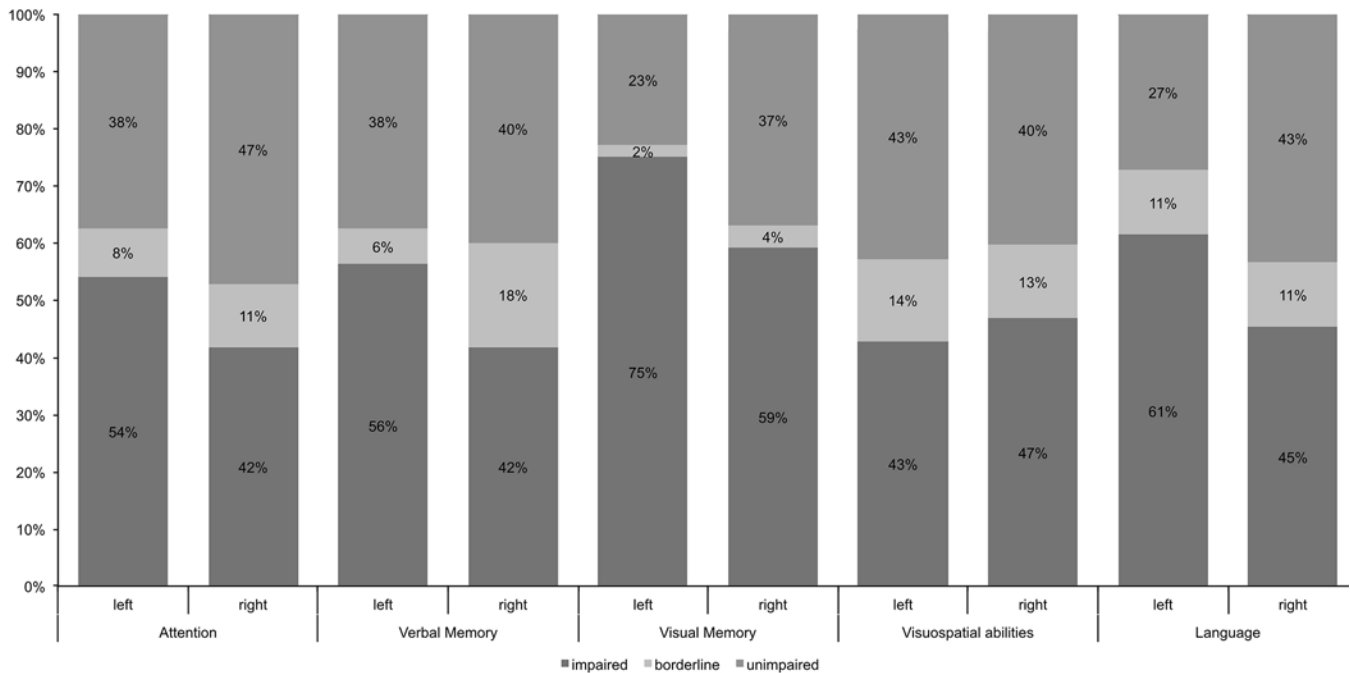
a favorable seizure outcome (ILAE class 1) was achieved in 75% of patients 1 year after surgery, which is consistent with published data.<sup>16–20</sup> Schmeiser et al. reported on a series of 458 patients with TLE who were treated with different surgical approaches. They found no differences in short- and long-term seizure outcomes in regard to surgical approach.<sup>16</sup> Other studies addressing this aspect have shown comparable results regarding the seizure outcome between standard temporal lobectomy and sAHE.<sup>21,22</sup> The systematic review and meta-analysis by Josephson et al. shows that ATL is slightly more effective than sAHE regarding seizure outcome.<sup>18</sup> Some authors have reported that sAHE may carry the risk of seizure recurrence in patients with an unrecognized lateral temporal epileptogenic zone.<sup>23</sup> The analysis in this current series revealed that surgical modality did not have an impact on seizure outcome. The overall complication rate in our series was 11.8%, and a revision surgery was required in 8.1% of all patients. However, the reported complication rates are difficult to compare due to different surgical approaches, different underlying pathologies, and heterogeneous study populations. Surgical site infections were the most common complications (5.6%) in our series, followed by bleeding complications (3.7%). The reported rate of infections ranges between 1.5% and 8.5%.<sup>24,25</sup> The occurrence rate of new postoperative motor deficits (hemiparesis) as reported by Erba et al.<sup>25</sup> was 4.3%, and 1.2% in the series by Schmeiser et al.<sup>16</sup> In our series, hemiparesis occurred in 4.9% of patients and was completely resolved in all patients during the observation period. With respect to newly occurring neurological deficits, the comparison of patients with favorable and unfavorable outcomes in our series revealed no impact on seizure outcome. VFDs are a common side effect after TLS. Due to inconsistent and different definitions, the reported rate of VFDs has a very wide range (between 1.5% and 69%).<sup>24</sup> In their study, Schmeiser et al. reported on a large cohort of patients suffering from TLE (overall rate of 73%).<sup>26</sup> In patients who underwent ATL the overall rate was 83%, and in patients who underwent transylvian sAHE the rate was 74%. In the current series, the overall rate of postoperative VFD is consistent with the reported literature. However, our results did not reveal any differences between selective and nonselective surgical procedures. Due to the fact that at our institution the sAHE was performed exclusively via a transylvian approach, there are some limitations with regard to comparability of the data with other studies.

As mesiotemporal and neocortical structures play an important role in memory function, postoperative memory impairment is a major sequela after rTLS. In the current series, left TLE patients were generally more impaired

**TABLE 3. Seizure outcome according to ILAE classification at 6- and 12-month follow-up visits**

Follow-Up (mos)	ILAE Classification						Total
	1	2	3	4	5	6	
6	121 (75.2)	9 (5.6)	11 (6.8)	10 (6.2)	8 (5.0)	2 (1.2)	161
12	121 (75.2)	10 (6.2)	8 (5.0)	10 (6.2)	10 (6.2)	2 (1.2)	161

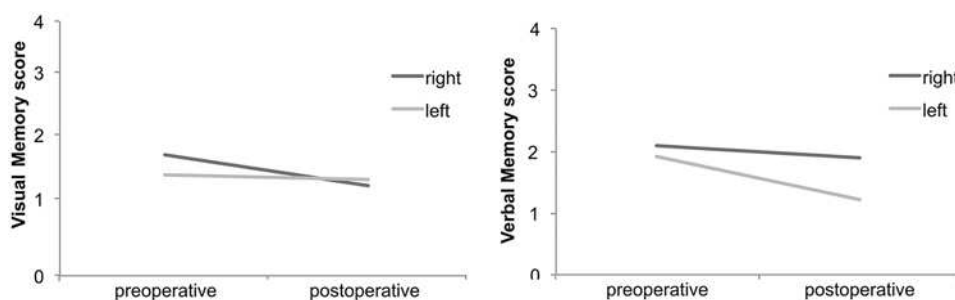
Data are given as number (%).



**FIG. 1.** Comparative histogram demonstrates the results of the preoperative cognitive performance. The results from each cognitive domain are summarized and classified into a 5-point scale ranging from severely impaired to above average. The values represent cumulative percentage of performance categories in each tested cognitive domain according to the side of the TLE. Impaired = cumulative percentages of impaired and severely impaired performance categories; unimpaired = cumulative percentages of unimpaired and above-average performance categories; borderline = percentages of borderline performance categories. Visual memory was impaired in 66% of patients, followed by verbal memory, language, and attention in approximately 50% each, respectively. Visuospatial functions were affected in 39% of cases. Preoperatively there were no significant differences in performance between left and right TLE ( $p > 0.29-0.80$ ).

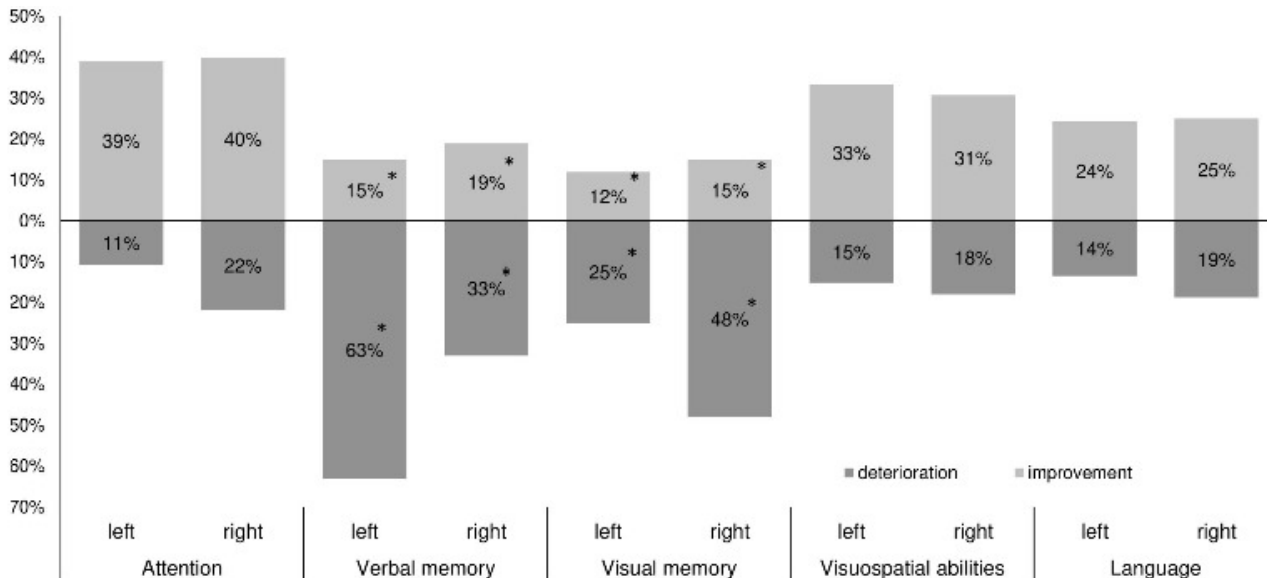
than right TLE patients, and verbal learning and memory deteriorated similarly in both groups. Language and visuospatial abilities did not show significant changes. Our findings are consistent with comparable previously published studies in which deterioration of verbal memory has been observed after left-sided resections and visual memory deterioration has been observed after right-sided resections.<sup>16,27</sup> Selective attention significantly improved after surgery, which could be due to the relatively high number of seizure-free patients in our study cohort.<sup>28</sup>

In a meta-analysis on a total of 3511 patients reported by Tonini et al., the authors found that intracranial monitoring was a predictor for unfavorable seizure outcome.<sup>29</sup> In accordance with these results, in the current series we found significantly more patients in the group with unfavorable seizure outcome who underwent invasive presurgical evaluation with depth electrodes. Interestingly, in multivariate logistic regression analysis in our series, this variable failed to be an independent predictor for an unfavorable seizure outcome. According to published data,



**FIG. 2.** Performance in visual and verbal memory before and after surgery according to the side of the resection. Group-level analysis revealed an interaction effect of visual memory and surgical side ( $F [1,99] = 4.752$ ,  $p = 0.032$ ,  $\eta^2 = 0.046$ ). Patient performance was worse after right-sided resections than after left-sided resections (*left*). In addition, a significant main effect of surgery ( $F [1,101] = 10.831$ ,  $p < 0.01$ ,  $\eta^2 = 0.097$ ) and a significant main effect of surgical side ( $F [1,101] = 4.379$ ,  $p < 0.05$ ,  $\eta^2 = 0.042$ ) was found for verbal learning and memory. There was a trend for an interaction of side and surgery ( $F [1,101] = 3.127$ ,  $p = 0.08$ ,  $\eta^2 = 0.03$ ) (*right*).





**FIG. 3.** Postoperative changes in performance categories according to side of resection. The histogram displays the number of patients with significant individual changes, corrected for floor effects. To account for floor effects, patients with the lowest possible baseline score without postoperative change were filtered. We identified 13 patients with floor effects in verbal memory, 15 patients in visual memory, 3 patients in attention, 2 patients in visuospatial abilities, and 1 in the language domain. This revealed a higher rate of postoperative decline in verbal memory after left-sided resections ( $\chi^2 [2] = 9.160, p = 0.01$ ). The other findings remained the same as in the whole sample. Considering ceiling effects, the results were not significantly different from the results obtained from the whole sample. The bars for verbal and visual memory exclude patients with floor effects. The asterisks represent significant postoperative changes.

about 20%–30% of patients with TLE have normal MRI without epileptogenic lesions.<sup>30,31</sup> The reported rates of seizure-free outcome following rTLS in these patients varied widely, between 20% and 80%.<sup>32,33</sup> In our studied population, the overall rate of patients with MRI-negative TLE was 8.7%. There were significantly more patients (20%) with negative MRI in the group with unfavorable seizure outcome compared to the 5% in the group with favorable seizure outcome. In contrast to the data published by Tonini et al., in the multivariate logistic regression analysis in the present series, negative MRI also failed to be an independent prognostic factor for unfavorable seizure outcome. These findings suggest that a normal MRI and the need for invasive presurgical evaluation are not always associated with worse postoperative seizure outcome. This suggestion can be supported by data reported by Sotero de

Menezes et al.<sup>34</sup> and Roberts et al.<sup>35</sup> showing that seizure outcome in patients with normal MRI is comparable to that in patients with abnormal MRI. Ivanovic et al. showed similar results in their analysis.<sup>33</sup>

Regarding the histopathological findings, there are several studies suggesting that HS and its distinct pattern may predict surgical outcome in patients with TLE.<sup>36–38</sup> According to the ILAE Task Force, neuronal loss may affect all of the areas of the cornu ammonis (CA; HS ILAE type 1), predominantly CA1 (HS ILAE type 2), or predominantly CA4 (HS ILAE type 3).<sup>8</sup> Another pattern described in surgical specimens is astrogliosis without neuronal loss, and it is called “no hippocampal sclerosis, gliosis only.” It is unclear whether HG precedes neuronal loss leading to HS or whether it is a distinct disease entity. The data evaluating the impact of HG on seizure outcome

**TABLE 4.** Occurrence of VFDs according to surgical procedures

Variable	Surgical Procedures		
	Overall	Selective	Nonselective
No. of procedures	161	91	70
No VFD	79 (49)	39 (43)	40 (57)
VFD w/ superior quadrantanopia	65 (40)	43 (47)	22 (32)
VFD w/ homonymous hemianopia	17 (11)	9 (10)	8 (11)
Total	161 (100)	91 (100)	70 (100)

Data are given as number (%). All comparisons of VFDs between surgical groups were nonsignificant.

**TABLE 5. Multivariate logistic regression analysis of factors related to unfavorable seizure outcome (ILAE class 2–6)**

Factor Analyzed	Seizure Outcome		Multivariate Analysis		
	Group I, n = 121	Group II, n = 40	OR	95% CI	p Value
Invasive presurgical evaluation w/ depth electrodes	21 (17.4%)	15 (37.5%)	2.01	0.8–5.1	0.144
Preop MRI w/o lesion	6 (5%)	8 (20%)	1.44	0.3–6.5	0.633
Histopathological evidence of HS	77 (63.6%)	17 (42.5%)	1.60	0.7–3.8	0.295
Histopathological evidence of HG	10 (8.3%)	11 (27.5%)	4.99	1.9–13.1	0.001
Incomplete resection	2 (1.7%)	4 (10%)	9.08	1.6–52.5	0.014

in patients with TLE following resective surgery is scarce. The majority of the literature is focused on evaluation of the impact of HS on postsurgical seizure outcome. However, the identification of HG as an independent predictor for lack of seizure freedom in our series is an aspect that is underrepresented in the literature. Since ILAE developed a consensus classification of HS, several reports have been published to rule out the impact of subtypes of HS on postoperative seizure outcome. In their recently published series on 307 cases with TLE and HS, Gales et al. found no clear correlation between HS subtype and epilepsy surgery outcome.<sup>39</sup> Similar results were found by Deleo et al.<sup>40</sup> and Savitr Sastri et al.,<sup>41</sup> who showed no significant difference in short-term seizure outcome between patients with different HS subtypes. In their recently published series, Hattingen et al. found that patients with hippocampal “gliosis only” according to the ILAE classification have distinct histopathological and MRI patterns compared with HS.<sup>42</sup> In the current series, we did not distinguish between patient HS subtypes and seizure outcome. However, the analysis of histopathological features in our series revealed HS as the most frequent pathology. Furthermore, there were significantly more patients with HS in the group with favorable seizure outcome. In contrast, HG was found significantly more often in patients with unfavorable outcome. Yet, only HG was identified to be an independent predictor for unfavorable outcome in the multivariate logistic regression analysis. These findings may support the suggestion made by Hattingen et al., who identified HG as a distinct entity in patients with TLE. In our opinion, this finding is important given that several reports have recently been published describing features with the potential to distinguish between HG and HS on preoperative MRI using novel methods of neuroimaging.<sup>43</sup> Further progress in neuroimaging may allow us to detect the underlying pathology within the hippocampus more precisely on the preoperative scan. Thus, the fact that HG independently predicts seizure outcome is novel in relationship to prior publications.

The insufficient resection of epileptogenic structures is an obvious reason for continued seizures after epilepsy surgery.<sup>29,44</sup> The resection may prove difficult with structures involving eloquent brain area or those not easy to access surgically. There are several series reporting that further resection of residual epileptogenic structures can result in a seizure-free outcome.<sup>12,45</sup> This fact supports the suggestion that a subgroup of patients fail rTLS for TLE because of incomplete resection of mesial temporal structures. In accordance with these results, the analysis in our

series shows significantly more patients with incomplete resection on postoperative MRI in the group with unfavorable seizure outcome. The data in the current study also revealed the evidence of HG and an incomplete resection of the epileptogenic lesion as independent predictors of unfavorable postoperative seizure outcome. Furthermore, the analysis shows that even though there were nonsignificant differences, there was a much higher proportion of gliosis in the specimen obtained from temporal lobe tissue among patients without effects on the hippocampus and with unfavorable seizure outcome compared to the seizure-free group. This could be caused by the fact that neocortical temporal lesions without clearly circumscribed pathology are less resectable. Thus, such lesions might possibly have worse results for reasons related to the lesion itself, not to the surgery.

### Study Limitations

The present study has several limitations. One of the strengths of the present series is a relatively large study population, which was treated at a high-volume center in a standardized fashion. Our study suffers from the risk of bias inherent to retrospective cohort analysis. Even though data analysis was retrospective, data acquisition was prospective. However, the implementation of standardized neurosurgical approaches and strict variable definitions might mitigate some of the shortcomings of a retrospective study design.

### Conclusions

Our analysis shows that rTLS is an effective treatment method in patients with refractory TLE. However, patients with a lack of lesions on MRI and placement of depth electrodes prior to rTLS are at higher risk for an unfavorable postsurgical seizure outcome. Therefore, these facts should be carefully taken into account, and each of these patients needs an individual approach during the selection process for surgery.

### References

- Engel J Jr. Surgical treatment for epilepsy: too little, too late? *JAMA*. 2008;300(21):2548–2550.
- Wiebe S, Blume WT, Girvin JP, Eliasziw M. A randomized, controlled trial of surgery for temporal-lobe epilepsy. *N Engl J Med*. 2001;345(5):311–318.
- Engel J Jr, Wiebe S, French J, et al. Practice parameter: temporal lobe and localized neocortical resections for epilepsy: report of the Quality Standards Subcommittee of the Ameri-

- can Academy of Neurology, in association with the American Epilepsy Society and the American Association of Neurological Surgeons. *Neurology*. 2003;60(4):538–547.
4. Englot DJ, Chang EF. Rates and predictors of seizure freedom in resective epilepsy surgery: an update. *Neurosurg Rev*. 2014;37(3):389–405.
  5. Bien CG, Raabe AL, Schramm J, et al. Trends in presurgical evaluation and surgical treatment of epilepsy at one centre from 1988–2009. *J Neurol Neurosurg Psychiatry*. 2013;84(1):54–61.
  6. Kral T, Clusmann H, Urbach J, et al. Preoperative evaluation for epilepsy surgery (Bonn Algorithm). *Zentralbl Neurochir*. 2002;63(3):106–110.
  7. Wellmer J, von der Groeben F, Klarmann U, et al. Risks and benefits of invasive epilepsy surgery workup with implanted subdural and depth electrodes. *Epilepsia*. 2012;53(8):1322–1332.
  8. Blümcke I, Thom M, Aronica E, et al. International consensus classification of hippocampal sclerosis in temporal lobe epilepsy: a Task Force report from the ILAE Commission on Diagnostic Methods. *Epilepsia*. 2013;54(7):1315–1329.
  9. Louis DN, Perry A, Reifenberger G, et al. The 2016 World Health Organization Classification of Tumors of the Central Nervous System: a summary. *Acta Neuropathol*. 2016;131(6):803–820.
  10. Blümcke I, Thom M, Aronica E, et al. The clinicopathologic spectrum of focal cortical dysplasias: a consensus classification proposed by an ad hoc Task Force of the ILAE Diagnostic Methods Commission. *Epilepsia*. 2011;52(1):158–174.
  11. Wieser HG, Blume WT, Fish D, et al. ILAE Commission Report. Proposal for a new classification of outcome with respect to epileptic seizures following epilepsy surgery. *Epilepsia*. 2001;42(2):282–286.
  12. Grote A, Witt JA, Surges R, et al. A second chance—reoperation in patients with failed surgery for intractable epilepsy: long-term outcome, neuropsychology and complications. *J Neurol Neurosurg Psychiatry*. 2016;87(4):379–385.
  13. Sadek AR, Gray WP. Chopping and changing: long-term results of epilepsy surgery. *Lancet*. 2011;378(9800):1360–1362.
  14. McIntosh AM, Kalnins RM, Mitchell LA, et al. Temporal lobectomy: long-term seizure outcome, late recurrence and risks for seizure recurrence. *Brain*. 2004;127(Pt 9):2018–2030.
  15. Jeha LE, Najm IM, Bingaman WE, et al. Predictors of outcome after temporal lobectomy for the treatment of intractable epilepsy. *Neurology*. 2006;66(12):1938–1940.
  16. Schmeiser B, Wagner K, Schulze-Bonhage A, et al. Surgical treatment of mesiotemporal lobe epilepsy: which approach is favorable? *Neurosurgery*. 2017;81(6):992–1004.
  17. Hu WH, Zhang C, Zhang K, et al. Selective amygdalohippocampectomy versus anterior temporal lobectomy in the management of mesial temporal lobe epilepsy: a meta-analysis of comparative studies. *J Neurosurg*. 2013;119(5):1089–1097.
  18. Josephson CB, Dykeman J, Fiest KM, et al. Systematic review and meta-analysis of standard vs selective temporal lobe epilepsy surgery. *Neurology*. 2013;80(18):1669–1676.
  19. Malikova H, Kramská L, Vojtech Z, et al. Different surgical approaches for mesial temporal epilepsy: resection extent, seizure, and neuropsychological outcomes. *Stereotact Funct Neurosurg*. 2014;92(6):372–380.
  20. Wendling AS, Hirsch E, Wisniewski I, et al. Selective amygdalohippocampectomy versus standard temporal lobectomy in patients with mesial temporal lobe epilepsy and unilateral hippocampal sclerosis. *Epilepsy Res*. 2013;104(1-2):94–104.
  21. Schramm J. Temporal lobe epilepsy surgery and the quest for optimal extent of resection: a review. *Epilepsia*. 2008;49(8):1296–1307.
  22. Yaşargil MG, Krayenbühl N, Roth P, et al. The selective amygdalohippocampectomy for intractable temporal limbic seizures. *J Neurosurg*. 2010;112(1):168–185.
  23. Parrent AG, Blume WT. Stereotactic amygdalohippocampectomy for the treatment of medial temporal lobe epilepsy. *Epilepsia*. 1999;40(10):1408–1416.
  24. Georgiadis I, Kapsalaki EZ, Fountas KN. Temporal lobe resective surgery for medically intractable epilepsy: a review of complications and side effects. *Epilepsy Res Treat*. 2013;2013:752195.
  25. Erba G, Winston KR, Adler JR, et al. Temporal lobectomy for complex partial seizures that began in childhood. *Surg Neurol*. 1992;38(6):424–432.
  26. Schmeiser B, Daniel M, Kogias E, et al. Visual field defects following different resective procedures for mesiotemporal lobe epilepsy. *Epilepsy Behav*. 2017;76:39–45.
  27. Helmstaedter C, Richter S, Röske S, et al. Differential effects of temporal pole resection with amygdalohippocampectomy versus selective amygdalohippocampectomy on material-specific memory in patients with mesial temporal lobe epilepsy. *Epilepsia*. 2008;49(1):88–97.
  28. Helmstaedter C, Elger CE, Witt JA. The effect of quantitative and qualitative antiepileptic drug changes on cognitive recovery after epilepsy surgery. *Seizure*. 2016;36:63–69.
  29. Tonini C, Beghi E, Berg AT, et al. Predictors of epilepsy surgery outcome: a meta-analysis. *Epilepsy Res*. 2004;62(1):75–87.
  30. Carne RP, O'Brien TJ, Kilpatrick CJ, et al. MRI-negative PET-positive temporal lobe epilepsy: a distinct surgically remediable syndrome. *Brain*. 2004;127(Pt 10):2276–2285.
  31. Téllez-Zenteno JF, Hernández Ronquillo L, Moien-Afshari F, Wiebe S. Surgical outcomes in lesional and non-lesional epilepsy: a systematic review and meta-analysis. *Epilepsy Res*. 2010;89(2-3):310–318.
  32. Bien CG, Szinay M, Wagner J, et al. Characteristics and surgical outcomes of patients with refractory magnetic resonance imaging-negative epilepsies. *Arch Neurol*. 2009;66(12):1491–1499.
  33. Ivanovic J, Larsson PG, Østby Y, et al. Seizure outcomes of temporal lobe epilepsy surgery in patients with normal MRI and without specific histopathology. *Acta Neurochir (Wien)*. 2017;159(5):757–766.
  34. Sotero de Menezes MA, Connolly M, Bolanos A, et al. Temporal lobectomy in early childhood: the need for long-term follow-up. *J Child Neurol*. 2001;16(8):585–590.
  35. Roberts DW, Jobst BC, Siegel AM, et al. Investigation of extra-temporal epilepsy. *Stereotact Funct Neurosurg*. 2001;77(1-4):216–218.
  36. de Lanerolle NC, Kim JH, Williamson A, et al. A retrospective analysis of hippocampal pathology in human temporal lobe epilepsy: evidence for distinctive patient subcategories. *Epilepsia*. 2003;44(5):677–687.
  37. Blümcke I, Pauli E, Clusmann H, et al. A new clinico-pathological classification system for mesial temporal sclerosis. *Acta Neuropathol*. 2007;113(3):235–244.
  38. Thom M, Liagkouras I, Elliot KJ, et al. Reliability of patterns of hippocampal sclerosis as predictors of postsurgical outcome. *Epilepsia*. 2010;51(9):1801–1808.
  39. Gales JM, Jehi L, Nowacki A, Prayson RA. The role of histopathologic subtype in the setting of hippocampal sclerosis-associated mesial temporal lobe epilepsy. *Hum Pathol*. 2017;63:79–88.
  40. Deleo F, Garbelli R, Milesi G, et al. Short- and long-term surgical outcomes of temporal lobe epilepsy associated with hippocampal sclerosis: relationships with neuropathology. *Epilepsia*. 2016;57(2):306–315.
  41. Savitr Sastri BV, Arivazhagan A, Sinha S, et al. Clinico-pathological factors influencing surgical outcome in drug resistant epilepsy secondary to mesial temporal sclerosis. *J Neurol Sci*. 2014;340(1-2):183–190.
  42. Hattingen E, Enkirch SJ, Jurcoane A, et al. Hippocampal “gliosis only” on MR imaging represents a distinct entity in epilepsy patients. *Neuroradiology*. 2018;60(2):161–168.

43. Bernhardt BC, Fadaie F, Liu M, et al. Temporal lobe epilepsy: hippocampal pathology modulates connectome topology and controllability. *Neurology*. 2019;92(19):e2209–e2220.
44. Paolicchi JM, Jayakar P, Dean P, et al. Predictors of outcome in pediatric epilepsy surgery. *Neurology*. 2000;54(3):642–647.
45. Harroud A, Bouthillier A, Weil AG, Nguyen DK. Temporal lobe epilepsy surgery failures: a review. *Epilepsy Res Treat*. 2012;2012:201651.

---

### Disclosures

Dr. Helmstaedter reports receiving honoraria from UCB, Eisai, Precisis, and GW; receiving royalties from EpiTrack and NeuroCog FX; and being a consultant to Eisai, UCB, Precisis, and GW. Ms. Taube received support of non–study-related clinical or research effort from the University Hospital Bonn Department of Epileptology (European Reference Network EpiCARE Grant).

### Author Contributions

Conception and design: Borger, Vatter. Acquisition of data: Borger, Hamed, Taube, Aydin, Ilic, Schneider, Becker. Analysis and interpretation of data: Borger, Taube, Helmstaedter, Vatter. Drafting the article: Borger. Critically revising the article: Schuss,

Güresir, Becker, Helmstaedter, Elger, Vatter. Reviewed submitted version of manuscript: Hamed, Taube, Aydin, Ilic, Schneider, Schuss, Güresir, Becker, Helmstaedter, Elger, Vatter. Approved the final version of the manuscript on behalf of all authors: Borger. Statistical analysis: Borger, Taube. Administrative/technical/material support: Helmstaedter, Elger, Vatter.

### Supplemental Information

#### Previous Presentations

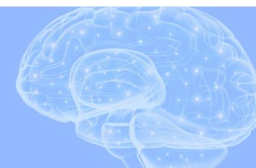Parts of this work were presented orally at the 69th Annual Meeting of the German Society of Neurosurgery in Münster, Germany, June 3–6, 2018, and at the 13th European Congress on Epileptology in Vienna, Austria, August 26–30, 2018.

#### Correspondence


Valeri Borger: University Hospital Bonn, Germany.  
valeri.borger@ukbonn.de.



### 3.2 Publication 2: 'Hippocampal innate inflammatory gliosis only' in pharmacoresistant temporal lobe epilepsy



## ‘Hippocampal innate inflammatory gliosis only’ in pharmaco-resistant temporal lobe epilepsy

 Alexander Grote,<sup>1†</sup> Dieter-Henrik Heiland,<sup>2,†</sup> Julia Taube,<sup>3</sup> Christoph Helmstaedter,<sup>3</sup> Vidhya M. Ravi,<sup>2</sup> Paulina Will,<sup>2</sup> Elke Hattingen,<sup>4</sup> Jan-Rüdiger Schüre,<sup>4</sup> Juri-Alexander Witt,<sup>3</sup> Annika Reimers,<sup>5</sup> Christian Elger,<sup>6</sup> Johannes Schramm,<sup>7</sup> Albert J. Becker<sup>5,‡</sup> and Daniel Delev<sup>8,‡</sup>

†,‡These authors contributed equally to this work.

Drug-resistant mesial-temporal lobe epilepsy is a devastating disease with seizure onset in the hippocampal formation. A fraction of hippocampi samples from epilepsy-surgical procedures reveals a peculiar histological pattern referred to as ‘gliosis only’ with unresolved pathogenesis and enigmatic sequelae. Here, we hypothesize that ‘gliosis only’ represents a particular syndrome defined by distinct clinical and molecular characteristics.

We curated an in-depth multiparameter integration of systematic clinical, neuropsychological as well as neuropathological analysis from a consecutive cohort of 627 patients, who underwent hippocampectomy for drug-resistant temporal lobe epilepsy. All patients underwent either classic anterior temporal lobectomy or selective amygdalohippocampectomy. On the basis of their neuropathological exam, patients with hippocampus sclerosis and ‘gliosis only’ were characterized and compared within the whole cohort and within a subset of matched pairs. Integrated transcriptional analysis was performed to address molecular differences between both groups.

‘Gliosis only’ revealed demographics, clinical and neuropsychological outcome fundamentally different from hippocampus sclerosis. ‘Gliosis only’ patients had a significantly later seizure onset (16.3 versus 12.2 years,  $P=0.005$ ) and worse neuropsychological outcome after surgery compared to patients with hippocampus sclerosis. Epilepsy was less amendable by surgery in ‘gliosis only’ patients, resulting in a significantly worse rate of seizure freedom after surgery in this subgroup (43% versus 68%,  $P=0.0001$ , odds ratio = 2.8, confidence interval 1.7–4.7). This finding remained significant after multivariate and matched-pairs analysis. The ‘gliosis only’ group demonstrated pronounced astrogliosis and lack of significant neuronal degeneration in contrast to characteristic segmental neuron loss and fibrillary astrogliosis in hippocampus sclerosis. RNA-sequencing of gliosis only patients deciphered a distinct transcriptional programme that resembles an innate inflammatory response of reactive astrocytes.

Our data indicate a new temporal lobe epilepsy syndrome for which we suggest the term ‘Innate inflammatory gliosis only’. ‘Innate inflammatory gliosis only’ is characterized by a diffuse gliosis pattern lacking restricted hippocampal focality and is poorly controllable by surgery. Thus, ‘innate inflammatory gliosis only’ patients need to be clearly identified by presurgical examination paradigms of pharmaco-resistant temporal lobe epilepsy patients; surgical treatment of this subgroup should be considered with great precaution. ‘Innate inflammatory gliosis only’ requires innovative pharmacotreatment strategies.

1 Clinic for Neurosurgery, University Hospital of Marburg, 35033 Marburg, Germany

2 Clinic for Neurosurgery, University Medical Center Freiburg, 79106 Freiburg, Germany

Received January 04, 2022. Revised July 03, 2022. Accepted July 31, 2022. Advance access publication August 18, 2022

© The Author(s) 2022. Published by Oxford University Press on behalf of the Guarantors of Brain.

This is an Open Access article distributed under the terms of the Creative Commons Attribution-NonCommercial License (<https://creativecommons.org/licenses/by-nc/4.0/>), which permits non-commercial re-use, distribution, and reproduction in any medium, provided the original work is properly cited. For commercial re-use, please contact [journals.permissions@oup.com](mailto:journals.permissions@oup.com)

- 3 Clinic for Epileptology, University Hospital of Bonn, 53127 Bonn, Germany
- 4 Department of Neuroradiology, Hospital of Goethe University Frankfurt, 60528 Frankfurt am Main, Germany
- 5 Institute of Neuropathology, Section for Translational Epilepsy Research, University Hospital of Bonn, 53127 Bonn, Germany
- 6 Clinic for Neurology and Competence Center for Epilepsy, Beta Klinik Bonn GmbH, 53227 Bonn, Germany
- 7 Medical Faculty, University Medical Center Bonn, 53127 Bonn, Germany
- 8 Department of Neurosurgery, Faculty of Medicine, RWTH Aachen University, 52074 Aachen, Germany

Correspondence to: Alexander Grote  
 UKGM—Klinik für Neurochirurgie Baldingerstraße  
 35033 Marburg, Germany  
 E-mail: Alexander.grote@gmail.com

**Keywords:** epilepsy surgery; innate inflammation; gliosis only; seizure outcome; neuropsychology

## Introduction

Drug-resistant, mesial-temporal lobe epilepsy (MTLE) is one of the most common epilepsy forms eligible for operative treatment.<sup>1</sup> Surgery for MTLE is considered a safe and standardized therapy option proven to have better results than conservative management in properly selected cases.<sup>2</sup> The most common histopathological finding after surgery for MTLE is hippocampal sclerosis (HS),<sup>1</sup> which is characterized by neuronal cell loss and various degrees of gliosis, is classified in three distinct groups according to the recent International League Against Epilepsy classification scheme (ILAE 1–3),<sup>3</sup> mainly on the basis of differences in the segmental neuronal cell loss pattern. Despite the clinical and electrophysiological evidence of a mesiotemporal seizure origin, 20% of all resected hippocampi do not reveal significant neuronal cell loss but rather a variable expression of astrogliosis and are referred to as ILAE ‘no-HS’. While the first three types of HS have been investigated intensively with respect to etiopathogenetic aspects and postsurgical outcome,<sup>1,4–8</sup> ‘no-HS’ remains enigmatic in these regards.

In an MRI-negative series of patients undergoing surgery for MTLE, ‘no-HS’ can be even found in up to 80% of patients.<sup>9</sup> Recently, we reported an algorithm that enables the radiological identification of hippocampi without significant neuronal rarefaction on the preoperative MRI, comprising subtle bilateral changes and less signal intensity. Thus, we concluded this pattern to represent a distinct disease entity involved in epileptogenesis.<sup>10</sup> Since the neuropathological hallmark of ‘no-HS’ is given by the lack of segmental neurodegeneration and extensive cellular astrogliosis,<sup>11</sup> instead of fibrillary<sup>12</sup> scar-type astrogliosis typically found in HS, we preferred to coin this hippocampal lesion pattern according to most prominent pathological feature ‘gliosis only’ and will use this term in the present study. ‘Gliosis only’ has, however, remained controversial since it has been also claimed to represent a ‘pre-HS’ stage in individual MTLE patients instead of a distinct pathological pattern.

On the basis of these precedents, we have here systematically scrutinized the hypothesis that ‘gliosis only’ does not only constitute a neuropathological pattern different from HS but defines a distinct MTLE form with respect to clinical and neuropathological aspects and pathomechanisms mediating epileptogenicity of the affected hippocampal formations. To approach this hypothesis, we examined demographic, neuropsychological and surgical outcome differences between two large ‘gliosis only’ and HS collectives. On the

basis of a translational framework, we performed an integrated transcriptomic profiling, which revealed that ‘gliosis only’ possesses a characteristic, inflammatory-associated transcriptional signature. Taken together, our data show that ‘gliosis only’ resembles a distinct phenotype of MTLE, which we refer to as ‘innate inflammatory gliosis only’ (I<sup>2</sup>GO). I<sup>2</sup>GO is less curable by surgery, a finding that urgently argues for an important reconsideration of future diagnostic and clinical practice during the treatment of MTLE.

## Materials and methods

### Study population

The authors retrospectively searched the database of the Institute of Neuropathology at the University Hospital of Bonn for the results ‘hippocampus sclerosis’ and ‘gliosis only’. A total count of 815 matched this search. Only patients with the distinct histopathological finding of ‘hippocampus sclerosis’ or ‘gliosis only’ in the hippocampal specimen, who underwent either selective amygdalohippocampectomy (sAHE) or anterior temporal lobectomy between 1990 and 2012 at the Clinic for Neurosurgery of the University Hospital at Bonn Medical Center, were included in the study (local ethical board approval 229/00). Finally, 627 patients fulfilled the eligibility criteria. Clinical data were retrospectively obtained either from patients’ records or from the neurosurgical electronic database. Patients with dual pathology or other type of surgeries (e.g. disconnective procedures) were excluded ( $n = 188$ ). All patients were evaluated and selected for surgical treatment following a standardized protocol at a tertiary epilepsy centre at the Clinic of Epileptology, University Hospital of Bonn. Only patients with drug-resistant epilepsy were included. Limbic encephalitis was excluded in all patients either by clinical or laboratory examinations. Presurgical evaluation was performed as described by Kral et al.<sup>13</sup>

### Matched-pair analysis

To avoid potential statistical confounders caused by the different sample size (‘hippocampus sclerosis’ = 557; ‘gliosis only’ = 70) a subgroup matched-pair analysis was additionally performed. For this purpose, each patient with ‘gliosis only’ was matched to a patient with HS by sex, type of surgery [anterior temporal lobe resection (ATL) or sAHE], side of surgery and age at surgery (with a tolerated variance of  $\pm 2$  years).

## Statistical analysis

We used open-source software for statistical analysis from the jamovi project (2021: jamovi v.2.0, computer software retrieved from <https://www.jamovi.org>).<sup>14</sup> Standard procedures (Pearson, Wilcoxon and Fisher's exact tests, linear-by-linear association and Student's t-test) were used for univariate analyses as indicated. P-values <0.05 were considered to be significant. Confidence intervals (CI) are given as 95%. For multivariate analyses, we used Cox regression modelling (inclusion procedure).

## Histopathological evaluation

All histological assessments were re-evaluated for this study. The neuropathological standard procedure for epilepsy surgery specimens has been described in detail elsewhere.<sup>15</sup> In brief, surgical specimens were fixed in formaldehyde overnight and embedded into paraffin. Macroscopic and histopathological examinations were performed by experienced neuropathologists. The microscopic examination included haematoxylin and eosin (HE) staining and immunohistochemistry (IHC) with antibodies against neuronal nuclear specific protein (NeuN, Chemicon) and glial fibrillary acid protein (GFAP, Dako). Semiquantitative estimates of the range of hippocampal cell loss and astrogliosis were determined as described in detail in the [Supplementary material](#).

## RNA isolation from formalin-fixed, paraffin-embedded samples

Specimens were neuropathologically re-evaluated and care was taken to have neuroanatomically optimally preserved starting material for the asservation of up to 10 serial 10 µm sections to reach equivalent amounts of starting material for all cases. HS cases that were included here, fulfilled ILEA type 1 criteria. The tubes containing formalin-fixed, paraffin-embedded (FFPE) sections for RNA purification were stored at –80°C until use. The formalin fixed samples were thawed and RNA was extracted using the RNeasy FFPE Kit (Qiagen, Cat. No. 73540) according to the manufacturer's protocol. In brief, FFPE tissue sections were first deparaffinized at 56°C for 3 min followed by lysis with proteinase K for 15 min. The genomic DNA and small fragments of DNA were removed by adding DNase to the supernatant. Following two rounds of purification, concentrated RNA was purified using RNeasy MinElute spin columns and eluted in a volume of 30 µl of RNAase free water and stored at –80°C until use.

## Library preparation and sequencing

Since these lesions appear rarely, we used an optimized protocol to purify and sequence samples originating in some cases from up to 20-year-old paraffin embedded specimens. After thawing, the RNA concentration was measured on a Qubit 2.0 fluorometer (Thermo Fisher Scientific), and RNA quality was assessed using an Agilent 2100 Bioanalyzer (Agilent Technologies). ~100 ng total FFPE RNA was selected as an input as recommended. Poly-A enriched strand specific libraries were generated using RNA TruSeq Exome Kit consisting of TruSeq RNA Library Prep for Enrichment (Illumina, Cat. No. 20020189), TruSeq RNA Enrichment (Illumina, Cat. No. 20020490) and Illumina Exome Panel Enrichment Oligos (Illumina, Cat. No. 20020183) according to manufacturer's protocol. Illumina TruSeq RNA UD Indexes (Illumina, Cat. No. 20020591) were added to each sample and ligated cDNA was selectively enriched with 15 PCR cycles. Produced libraries were then quantified using

an Agilent 2100 Bioanalyzer DNA 1000 Kit (Agilent, Cat. No. 5067-1504) and a Qubit dsDNA HS Assay kit (ThermoFisher Scientific). In order to achieve a 4-plex library pool complexity, four unique precaptured cDNA libraries were combined into one pool (with a concentration of 200 ng each). Next, cDNA libraries were mixed with capture probes and hybridized probes were obtained using streptavidin magnetic beads. Captured libraries were cleaned up using AMPure XP beads (Beckman Coulter, Cat. No. A63881) before a 10-cycle PCR amplification. To block excess free adapters, Free Adapter Blocking Reagents (Illumina, Cat. No. 20024144) were added to each library pool according to the manufacturer's instructions, followed by another clean-up with AMPure XP beads. Libraries were normalized to 4 nM and combined, denatured and diluted to a final concentration of 1.1 pM. The library pool was loaded onto a MidOutput 150 cycles flowcell (Illumina, Cat. No. 20024907) and sequenced on Illumina's NextSeq 500 system. During sequencing, 65 cycles for reads 1 and 2 and 10 cycles for index 1 and 2 were used, and we obtained a cluster density of 194 K/mm<sup>2</sup>. Mapped reads were normalized by DESeq.

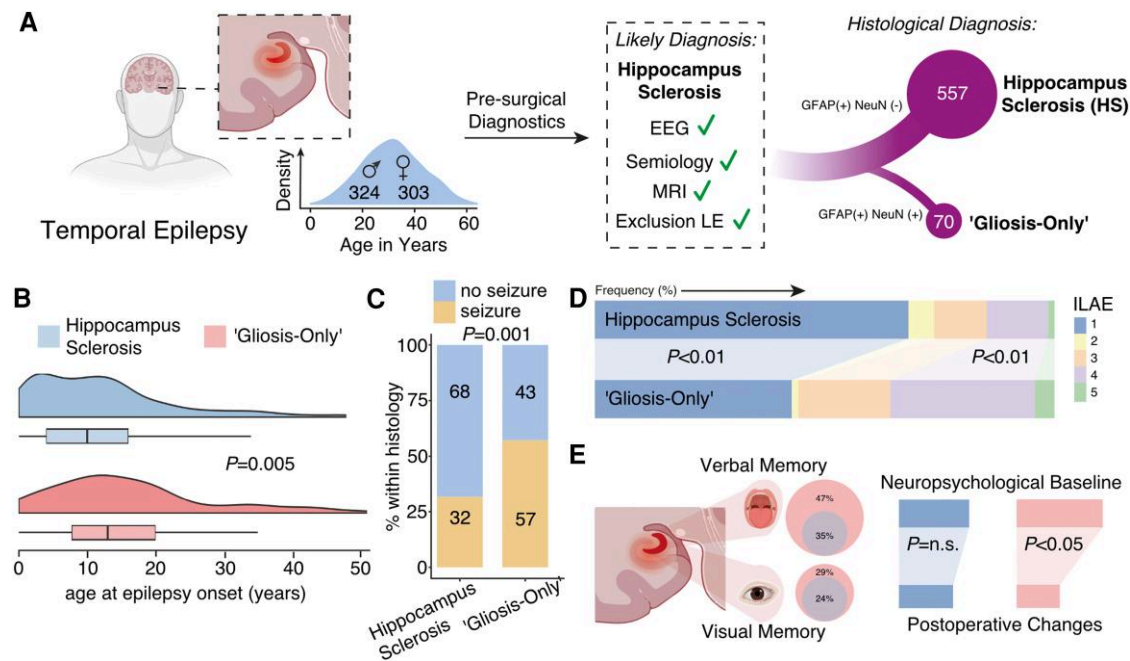
## Transcriptional data analysis

We performed supervised identification of marker genes across both groups using the AutoPipe package (R software, CRAN) as recently described.<sup>16</sup> To infer functional states, we performed gene set enrichment analysis and hypergeometric testing. Astrocytic states were projected in a 2D representation using the 4state plot function of SPATA2 (<https://github.com/theMILolab/SPATA2>) as recently described.<sup>16</sup>

## Neuropsychological assessment

Patients were neuropsychologically assessed before (T1) and one year after surgery (T2). The assessment, as previously described,<sup>17</sup> focuses on tests of verbal and non-verbal memory proven to be sensitive to temporal lobe pathology and the effects of temporal lobe surgery.<sup>18–22</sup> In addition, the assessment comprises measures of attention, executive functions, visuospatial abilities, language and motor functions. Verbal learning and memory were measured via the Verbaler Lern- und Merkfähigkeitstest<sup>23</sup> (VLMT), a German adaptation of the Rey Auditory Verbal Learning Test. For non-verbal learning and memory, we used the revised version of the Diagnosticum für Cerebralschädigung (DCS-R). Parallel versions of the VLMT and DCS-R were available to minimize practice effects at the follow-up. Attention was assessed by the EpiTrack and a letter cancellation task (d2 Aufmerksamkeitsbelastungstest). Language assessment comprised confrontation naming and a comprehension task (Token Test). Evaluation of motor functions included finger tapping, Luria motor task and Purdue Pegboard. The assessment consisted of visuospatial abilities by mental rotation (LPS subtest 7) and WAIS block design. The tests and their references are described in previous articles.<sup>17,23–25</sup>

Test results were first standardized based on age-corrected norms [mean = 100, standard deviation (SD) = 19]. In order to merge the various parameters within the respective domain, the scores were transformed into a five-point scale ranging from severely impaired to above average with the following operational definition, which has been used and published before<sup>26,27</sup>: severely impaired = 0, at least two test scores >2SD below the mean of the normative sample; impaired = 1, at least two test scores >1SD below the mean; borderline = 2, one test score below the mean; unimpaired = 3, no test score >1SD below the mean; and above average = 4, at least two test scores



**Figure 1** Demographics and clinical results. (A) Illustration of the workflow. A density plot at the bottom right indicates the age and gender distribution of all patients. Patient characteristics and distribution of histopathological findings after surgical resection for drug-resistant MTLE (LE = limbic encephalitis). (B) Patients with histopathological gliosis only developed epilepsy significantly later in life (seizure onset 12.2 years for HS versus 16.3 years for ‘gliosis only’,  $P = 0.005$ , one-sided t-test.). (C) Bar plot illustrates the postoperative epilepsy outcome in relation to neuropathological finding, Fisher’s exact test,  $P = 0.001$ . (D) Seizure outcome according to the ILAE classification, showing significant better postsurgical outcome in HS than ‘gliosis only’, one-way ANOVA. (E) Graphical summary of neuropsychological results—patients with ‘gliosis only’ reveal significant postoperative impairment in verbal and visual memory in relation to the preoperative baseline.

>1SD above the mean. The distance between two subsequent categories approximately corresponds to 1 SD from the mean standardized score across all test scores of the respective domain.<sup>28</sup> Neuropsychological change after surgery was defined as the intra-individual change in cognitive performance from pre- to postoperative assessment; the postoperative score was subtracted from the preoperative score in each domain. A positive value indicated improvement; a negative value indicated deterioration; a value of zero indicated no change.<sup>17</sup> Neuropsychological analysis was conducted for the matched-pairs sample. We used Chi-squared tests to assess preoperative differences and repeated-measures ANOVAs for postoperative changes on a group level with pathology and surgical side as between-subjects factors, as well as Chi-squared tests to assess individual postoperative changes.

## Data availability

The datasets generated during and/or analysed during the current study are available from the corresponding author on reasonable request.

## Results

### Study cohort

A total of 627 patients ( $n = 324$  female, 52%) with diagnosed drug-resistant MTLE due to presumed HS underwent standardized presurgical evaluation and were selected for surgical treatment (Fig. 1A). The complete diagnostic included at least 24 h long-term video-EEG, MRI and neuropsychological evaluation. Any clinical

uncertainty for limbic encephalitis was ruled out by examination of antineuronal or onconeuronal antibodies and complete patient examination for any unknown underlying tumour. None of the patients fulfilled the relevant integrated criteria for limbic encephalitis based on clinical, MRI as well as serological and neuropathological parameters.<sup>29,30</sup> The median duration of epilepsy was 22 [interquartile range (IQR) 18] years and median age of seizure onset was 11 (IQR 12) years. Invasive diagnostics was performed in 281 (44%) cases. A total of 497 (79%) patients were operated by sAHE, the remaining patients underwent standard ATL. The mean postoperative follow-up was 64.7 months. HS was found in 557 patients. ‘Gliosis only’ was diagnosed in the remaining 70 patients.

### Differences between HS and I<sup>2</sup>GO—seizure onset and seizure outcome

Due to the lack of significant cell loss, ‘gliosis only’ might be considered as a precursor state of early-onset HS. The demographic profiles of both cohorts described here, clearly argue against this concept. ‘Gliosis only’ patients developed epilepsy significantly later in life compared to their HS counterparts [median seizure onset: I<sup>2</sup>GO = 13 (IQR 12.25) years versus HS = 10 (IQR 12.0) years;  $P = 0.005$  two-sided t-test, Fig. 1B and Table 1], supporting the hypothesis that ‘gliosis only’ constitutes a distinct clinical–pathological condition.

Of note, anticonvulsive drug-resistance was reached in ‘gliosis only’ patients far more rapidly, consequently leading to an earlier inclusion for presurgical evaluation that resulted in significantly shorter duration of epilepsy [median duration of epilepsy: I<sup>2</sup>GO = 20 (IQR 17.5) years versus HS = 22 (IQR 19) years;  $P = 0.005$ ].



Table 1 Cohort description and univariate analysis

Parameter/condition	Sclerosis	I <sup>2</sup> GO <sup>b</sup>	Test statistic
<b>Whole cohort</b>	<b>(n = 557)</b>	<b>(n = 70)</b>	
Sex: female	0.5 288/557	0.5 36/70	P = 0.97 <sup>a</sup>
Onset of epilepsy, years	4.0 <b>10.0</b> 16.0	7.4 <b>13.0</b> 20.0	P < 0.01 <sup>b</sup>
Duration of epilepsy, years	14.0 <b>22.0</b> 33.0	8.4 <b>20.0</b> 26.6	P < 0.01 <sup>b</sup>
Age at surgery, years	28.0 <b>37.0</b> 45.3	24.9 <b>34.0</b> 44.1	P = 0.08 <sup>b</sup>
Side of surgery: right	0.5 261/557	0.5 38/70	P = 0.24 <sup>a</sup>
Type of surgery: sAHE	0.8 466/557	0.4 31/70	P < 0.01 <sup>a</sup>
Invasive EEG: no	0.6 324/555	0.3 20/70	P < 0.01 <sup>a</sup>
Outcome: seizure ILAE2-6	0.3 177/557	0.6 40/70	P < 0.01 <sup>a</sup>
<b>Matched pairs</b>	<b>(n = 70)</b>	<b>(n = 70)</b>	
Sex: female	0.5 36/70	0.5 36/70	P = 1.00 <sup>a</sup>
Onset of epilepsy, years	3.0 <b>9.0</b> 14.0	7.4 <b>13.0</b> 20.0	P < 0.01 <sup>b</sup>
Duration of epilepsy, years	16.0 <b>23.5</b> 31.1	8.4 <b>20.0</b> 26.6	P = 0.01 <sup>b</sup>
FBTCS: yes	0.4 29/70	0.6 41/70	P = 0.04 <sup>a</sup>
Seizures			
Focal aware	0.2 14/70	0.3 19/70	
Focal unaware	0.5 32/70	0.5 36/70	
Aware + unaware focal	0.3 24/70	0.2 15/70	P = 0.22 <sup>a</sup>
Interictal EEG			
bilateral features: yes	0.3 20/70	0.3 19/70	P = 0.85 <sup>a</sup>
Ictal EEG			
bilateral features: yes	0.4 27/70	0.3 18/70	P = 0.14 <sup>a</sup>
Invasive EEG: yes	0.6 39/70	0.7 50/70	P = 0.05 <sup>a</sup>
Invasive interictal EEG			
bilateral features: yes	0.1 4/39	0.0 2/50	P = 0.39 <sup>c</sup>
Invasive ictal EEG			
bilateral features: yes	0.3 10/39	0.1 5/50	P = 0.09 <sup>c</sup>
Early childhood convulsion: yes	0.3 22/70	0.4 28/70	P = 0.29 <sup>a</sup>
Traumatic brain injury: yes	0.0 1/70	0.1 5/70	P = 0.1 <sup>a</sup>
Age at surgery, years	25.0 <b>35.5</b> 43.1	24.9 <b>34.0</b> 44.1	P = 0.82 <sup>b</sup>
Side of surgery: right	0.6 39/70	0.5 38/70	P = 0.87 <sup>a</sup>
Type of surgery: sAHE	0.5 32/70	0.4 31/70	P = 0.87 <sup>a</sup>
Outcome: seizure: ILAE 2–6	0.4 25/70	0.6 40/70	P = 0.01 <sup>a</sup>

Cross table for univariate testing with categorical and continuous parameters for histology as the dependent variable. In the whole cohort parameters are calculated for the whole cohort (n = 627), while in matched-pairs parameters are calculated for the matched pair (n = 140) analysis. For continuous parameters the median value is printed bold and framed by its first and third quartiles (e.g. 4.0 10.0 16.0). Outcome is calculated for persisting epilepsy ILAE class 2–6. FBTCS = focal to bilateral tonic clonic seizure.

<sup>a</sup>Pearson.

<sup>b</sup>Wilcoxon.

<sup>c</sup>Fisher's exact test.

Univariate testing for categorical and continuous parameters regarding demographics is shown in Table 1.

Because of the skewed distribution between HS and 'gliosis only' patients, we additionally performed a matched-pairs analysis including detailed patients' characteristics. We matched patients with 'gliosis only' by gender, type and side of surgery and age at surgery (with a tolerance of  $\pm 2$  years) to a sclerosis counterpart and formed 70 pairs. In line with the results of the whole cohort analysis, seizure onset and duration of epilepsy showed significant differences between both groups, while other clinical characteristics (e.g. prior neurological insults, early childhood seizures, family history, interictal and ictal EEG) did not separate HS and I<sup>2</sup>GO.

One of the main clinical findings distinguishing I<sup>2</sup>GO from HS patients was the final seizure outcome. In general, surgery for MTLE is a successful treatment option with excellent seizure outcome. However, I<sup>2</sup>GO patients represent an important exception. At the last available outcome, only 43% (n = 30) of the I<sup>2</sup>GO patients were seizure free (ILAE1) compared to 68% (n = 380) of the HS cases [P = 0.0001, odds ratio (OR) = 2.8, CI 1.7–4.7] (Fig. 1C). This finding remained significant for other ILAE classes as well (Fig. 1D).

## I<sup>2</sup>GO is associated with unfavourable seizure outcome

Since other factors can influence final seizure outcome as well, we performed a multivariate logistic regression analysis testing the hypothesis that the underlying histology independently influences patients' outcomes. The analyses for the whole cohort (n = 627) confirmed 'gliosis only' (P < 0.0001, OR = 2.98, CI 1.73–5.16) as an independent predictor for worse seizure outcome after correcting for other variables known to influence the seizure outcome (Table 2, left panel, whole cohort analysis).

In line with these findings, histology of 'gliosis only' was also the only independent predictor, associated with worse seizure outcome in the multivariate matched-pair analysis (P = 0.030, OR = 2.182, CI 1.075–4.427, Table 2, right panel). Two additional multivariate models including further clinical variables (early childhood seizures, meningitis, number of anti-seizure medications and presence of focal to bilateral tonic clonic seizures) confirmed this finding showing a significant association between 'gliosis only' and poor seizure outcome (Supplementary Table 1).

Table 2 Binominal logistic regression for ILAE1 outcome

Predictor	Whole cohort (total n = 627; HS n = 557)				Matched pair (total n = 140, HS n = 70)			
	P	Odds ratio	95% CI		P	Odds ratio	95% CI	
			Lower	Upper			Lower	Upper
Side of surgery Right—Left	0.3132	0.820	0.557	1.205	0.916	1.038	0.512	2.116
Duration of epilepsy	0.3521	1.007	0.992	1.022	0.389	0.987	0.958	1.017
Type of surgery sAHE—ATL	0.2380	1.338	0.824	2.173	0.530	0.798	0.396	1.611
Invasive EEG No—Yes	<b>0.0378</b>	0.660	0.446	0.976	0.640	1.188	0.575	2.453
Histology 'gliosis only'—HS	<b>0.0009</b>	2.706	1.505	4.865	<b>0.030</b>	2.182	1.075	4.427

A binominal logistic regression analysis for the whole cohort ( $n=627$ ) and the matched-pair cohort ( $n=70$  pairs = 140 patients) with ILAE1 seizure outcome as the dependent variable. For the whole cohort, invasive EEG and the histology finding of gliosis only were independent prognostic factors for a worse seizure outcome. Within the matched-pair group, the analysis confirms 'gliosis only' as the only independent prognostic factor for worse seizure outcome while invasive EEG lost its influence for the seizure outcome. Estimates represent the log odds of 'outcome = seizures' versus 'outcome = seizure free'. Significant values are highlighted in bold.

### Gliosis only in I<sup>2</sup>GO differs from HS gliosis pattern

Neuropathologically, 'gliosis only' differs fundamentally from HS by neuronal cell density, fibrillary as well as cellular astrogliosis (Fig. 2).

In 'gliosis only', i.e. the neuropathological surrogate of I<sup>2</sup>GO, the combination of largely conserved neuronal densities accompanied by mainly a cellular reactive astrogliosis throughout all subfields is characteristic. The lesion pattern is in striking contrast to HS with pronounced segmental neurodegeneration in CA1, CA3 and CA4, whereas neuronal densities in CA2 and the dentate gyrus granular layer are rather conserved. Granule cell dispersion is seen in the HS pathology pattern (Fig. 2). Accordingly, semiquantitative neuron to glia ratios provide distinct fingerprints separating all different anatomical regions between the 'gliosis only' and HS patterns (Supplementary Fig. 2).

### I<sup>2</sup>GO is associated with a greater risk for cognitive decline

Complete neuropsychological data sets from before and after surgery were available for 46 patients with HS and 62 patients with 'gliosis only'. Before surgery, at baseline, 90% of the patients with HS and 'gliosis only' were impaired in at least one cognitive domain. Memory and language were most frequently affected (Table 3). Of note, 'gliosis only' patients showed slightly fewer impairments across the domains, and memory impairments tended to be less lateralized than in HS patients.

On a group level, verbal [ $F(1,107)=6.96, P<0.05$ ] and non-verbal memory [ $F(1,107)=4.01, P<0.05$ ] differed significantly between right and left TLE. There were no significant differences in attention, motor function and visuospatial abilities.

After surgery, 'gliosis only' patients declined more frequently in verbal memory (64%), and language (25%) after left TLR, and in non-verbal memory (26%) after right TLR than HS patients, who declined in 30, 15 and 17%, respectively. Extratemporal functions (attention, motor functions) also deteriorated more frequently in 'gliosis only'. Verbal memory decline was twice as likely in gliosis only than in HS [ $\chi^2(2)=7.14, P=0.03$ ]. A decline in language was more likely in 'gliosis only' than in HS [ $\chi^2(2)=5.07, P=0.08$ ].

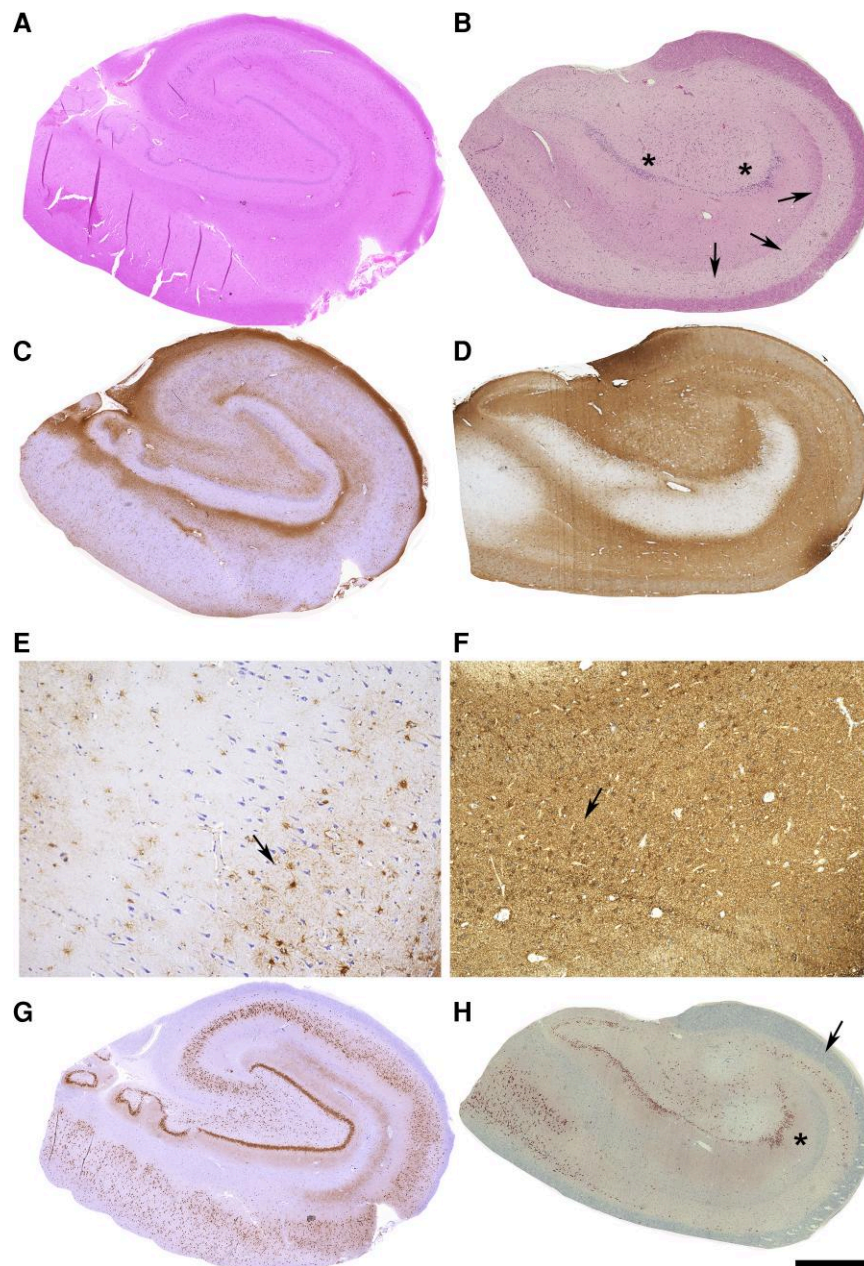
Repeated-measures ANOVAs revealed a significant main effect of surgery on the group level. Following resection, both groups showed cognitive decline in verbal [ $F(1,104)=7.19, P<0.05$ ] and non-verbal

memory [ $F(1,104)=6.71, P<0.05$ ]. Attention [ $F(1,103)=7.49, P<0.05$ ] and visuospatial abilities [ $F(1,94)=7.83, P<0.05$ ] improved rather than declined. Language and motor functions did not show significant postoperative changes on a group level.

### I<sup>2</sup>GO shows a unique gene-expression signature

Using RNA-sequencing we profiled 32 histologically defined HS and 'gliosis only' specimens. To avoid age and gender bias, we matched the samples on the basis of their clinical features. Out of 32 specimens, 24 reached quality control after library construction (Fig. 3A). The high dropout is caused by the fact that the tissue was up to 20 years old (paraffin embedded), which posed a challenge for RNA-sequencing. After combining unsupervised clustering with supervised analysis of differential expressed genes and correction for multiple testing (FDR) we identified a stable set of 265 genes, which marked the differences between classical HS and 'gliosis only' (Fig. 3B). We observed several transcripts encoding proteins with inflammatory-relevant function that were significantly upregulated in the 'gliosis only' including Apolipoprotein E (APOE2), C-C Motif Chemokine Ligand 2 (CCL2), Interleukin 1 Alpha (IL1A), Macrophage-Associated Antigen (CD163) and complement factors. Using gene set enrichment analysis, we confirmed an increase of inflammatory response and activation of the complement system (Fig. 3C). Additionally, other markers such as CD3D, Hepatitis A Virus Cellular Receptor 2 (HAVCR2) and Programmed Cell Death 1 (PDCD1) that are known hallmarks of chronic inflammation were significantly expressed in 'gliosis only' (Fig. 3C). To further classify our samples, we computed a two-dimensional classification model, which showed a shift of 'gliosis only' samples towards the signature genes defining the inflammatory state (Fig. 3D). This was further confirmed by aligning the inflammatory score to clinical features which revealed an exclusive inflammatory enhancement in the 'gliosis only' group not biased by other clinical parameters (Fig. 3E).

Since the major subtype of cells was reactively transformed astrocytes, we aimed to explore the linkage between 'gliosis only' astrocytes and common reactive subtypes. Using an unsupervised clustering of publicly available datasets of astrocytes from different CNS diseases and our transcriptional data, we were able to align our samples to known reactive subtypes. The transcriptional profile of HS clustered within a non-inflammatory reactive state similar to reactive astrocytes found in stroke or glial tumour samples. In contrast,



**Figure 2** Neuropathological differences in ‘gliosis only’ versus HS. (A) Hippocampal formation with the lesion pattern referred to as I<sup>2</sup>GO; note the virtual absence of neurodegeneration (HE staining). (B) HS ILAE type 1 with extensive segmental neurodegeneration pronounced CA 1 (arrows), CA3 and CA4 (asterisks). (C) Mainly cellular astroglia of the hippocampus is detected in I<sup>2</sup>GO (IHC with antibodies against GFAP). (D) Intense fibrillary astroglia predominates in HS (GFAP-IHC). (E) Reactive astroglial cells with large somata and delicate stellate processes are present in varying density virtually throughout all layers of the representative CA1 area high power magnification (GFAP-IHC); astroglial cells are occasionally clustered (arrow). Note that the neuronal density is largely conserved. (F) Higher power magnification in HS-CA1 reveals the presence of an extensive fibrillary astroglial matrix, which constitutes a scar-resembling pattern admixed to only rather sparse reactive astrocytes (arrow; GFAP-IHC). (G) NeuN-IHC underlines the virtual absence of neuronal loss in I<sup>2</sup>GO. (H) NeuN-IHC emphasizes granule cell dispersion (asterisk) and conservation of CA2 neurons (arrow) in addition to subtotal neurodegeneration in CA1 and CA3/4 in HS (bar graph corresponds to 1000  $\mu$ m in A–D, G and H; 200  $\mu$ m in E and F).

the histopathological ‘gliosis only’ showed astrocytes state similar to those observed in partially inflammatory diseases (Supplementary Fig. 1).

## Discussion

Surgery for drug-resistant MTLE is a safe, standardized and effective treatment option. However, it fails to achieve seizure freedom in

30–40% of the patients, suggesting that the underlying lesion of the mesial-temporal structures may not entirely cover the epileptogenic zone. ‘Gliosis only’, as we have recently coined this neuropathological pattern,<sup>10</sup> is a finding occurring in ~20% of the patients with MTLE included in the current ILAE classification as ‘no-HS’. Our results support the hypothesis that ‘gliosis only’ hallmarks a distinct disease entity with inflammation as underlying background, which we refer to as I<sup>2</sup>GO. I<sup>2</sup>GO is defined by a specific neuropathological

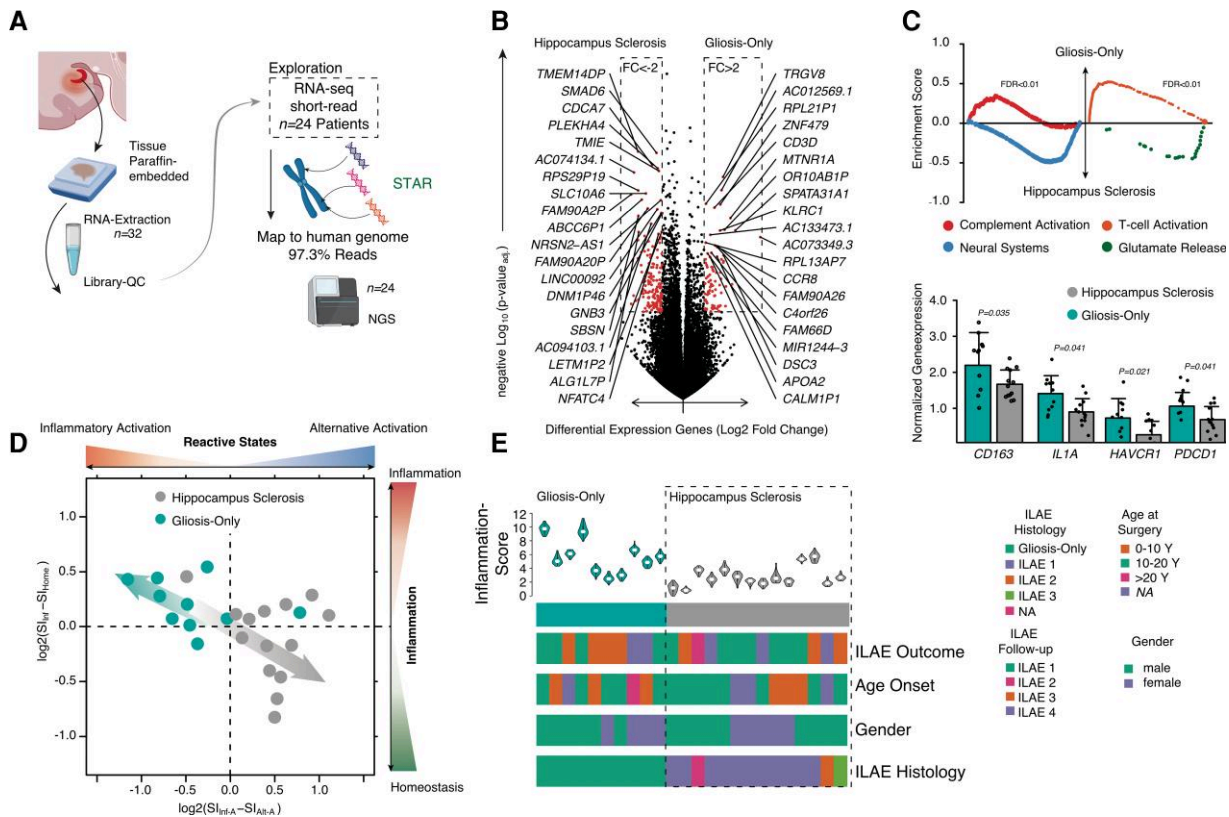


Table 3 Neuropsychological performance before and after surgery

		Left				Right			
		Impaired (T1)	Impaired (T2)	Losses	Gains	Impaired (T1)	Impaired (T2)	Losses	Gains
Attention	I <sup>2</sup> GO	61%	50%	11% <sup>a</sup>	25%	50%	50%	16% <sup>a</sup>	23%
	HS	70%	32%	5% <sup>a</sup>	45%	48%	52%	9% <sup>a</sup>	26%
Verbal memory	I <sup>2</sup> GO	75% <sup>a</sup>	89%	<b>64%</b>	14%	65% <sup>a</sup>	65%	32% <sup>a</sup>	39%
	HS	87% <sup>a</sup>	96%	<b>30%</b>	13%	61% <sup>a</sup>	78%	23% <sup>a</sup>	22%
Non-verbal memory	I <sup>2</sup> GO	54%	68%	36%	11%	77%	84%	26% <sup>a</sup>	10%
	HS	70%	74%	30%	13%	74%	87%	17% <sup>a</sup>	13%
Language	I <sup>2</sup> GO	71%	79%	25% <sup>a</sup>	4%	67%	53%	14% <sup>a</sup>	31%
	HS	77%	80%	15% <sup>a</sup>	25%	73%	67%	29% <sup>a</sup>	33%
Visuospatial abilities	I <sup>2</sup> GO	52%	48%	19%	15%	34%	24%	7%	25%
	HS	45%	30%	20%	45%	57%	48%	10%	45%
Motor functions	I <sup>2</sup> GO	60%	57%	35% <sup>a</sup>	30%	57%	50%	22%	33%
	HS	70%	63%	11% <sup>a</sup>	32%	63%	64%	15%	23%

T1 = preoperative; T2 = postoperative; losses/gains = change of at least 1 SD from pre- to postoperative performance. Significant differences are highlighted in bold.

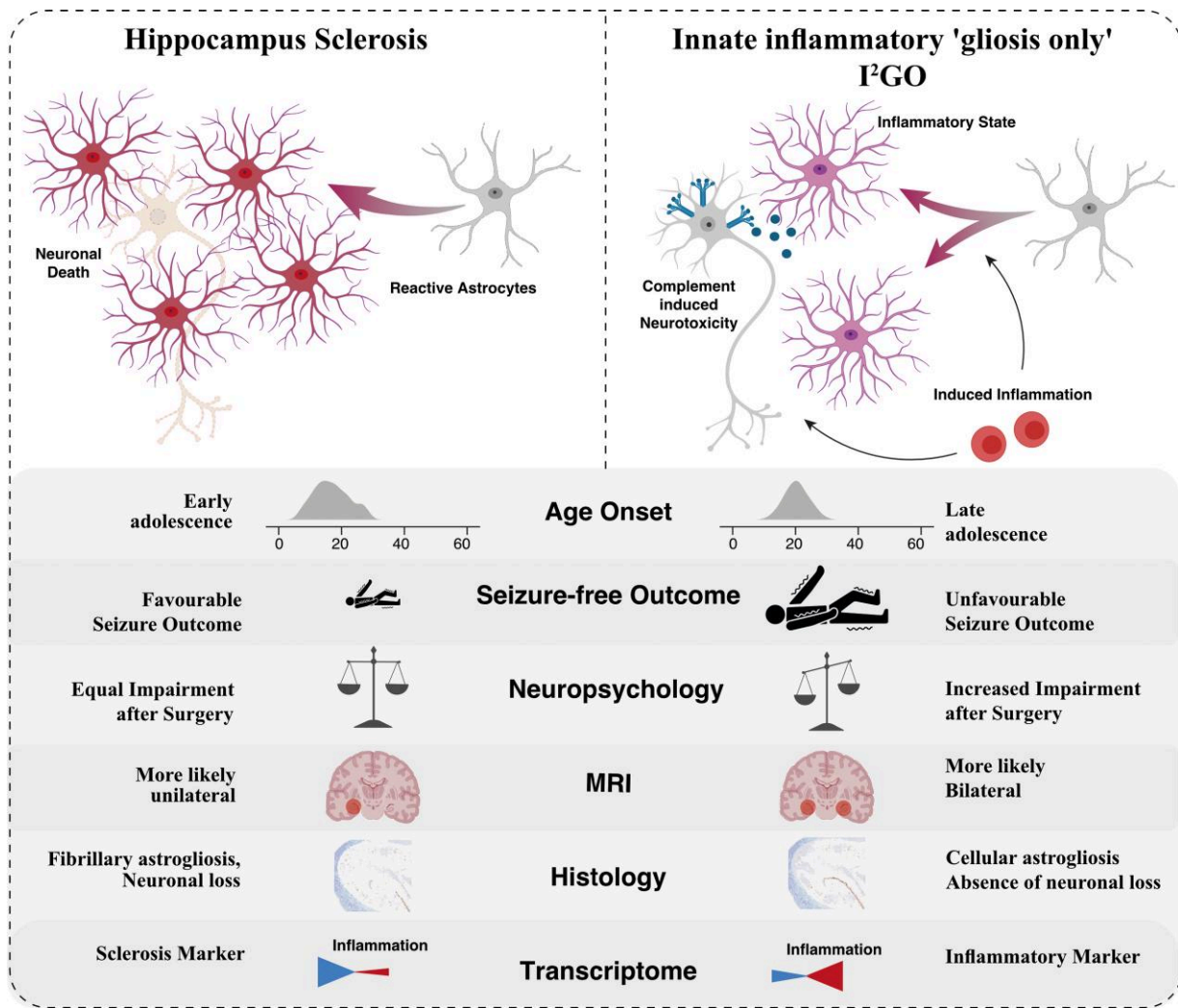
<sup>a</sup>Indicates a trend, but did not reach significance with  $P < 0.05$ .



**Figure 3 Transcriptional signature and gene expression.** (A) Illustration of the workflow. (B) Differential gene-expression analysis presented as a volcano plot. (C) Gene set enrichment analysis from the MSigDB (v.7.0) indicate significant enrichment of the complement and inflammatory response in ‘gliosis only’ samples and an upregulation of neuronal systems and glutamate release in HS samples, Kolmogorov–Smirnov-like test with adjustment of P-value using the false discovery rate. At the bottom, bar plots of gene-expression differences between ‘gliosis only’ and sclerosis samples using normalized gene-expression values. Wilcoxon rank with adjustment of the P-value by Benjamini–Hochberg. (D) 2D representation of astrocytic transformation. Each quadrant corresponds to a defined substate of reactive astrocytes, the illustrated position of each transcriptome reflects their relative scores for inflammatory-alternative activation (x-axis) and their grade of differentiation between adult and foetal programmes (y-axis). (E) Violin plot (top) indicates the individual inflammatory score calculated from mean expression of genes with inflammatory signatures with respect to the clinical information illustrated at the bottom.

pattern dominated by cellular gliosis, which renders a specific transcriptomic profile and follows a characteristic demographic and clinical patterns (Fig. 4) making it less curable by surgery supporting the inflammatory nature of the disease.

In line with these findings, two recent imaging studies have revealed characteristic structural and connectivity MRI patterns distinguishing ‘gliosis only MRI-negative’- and ‘HS-caused’-MTLE.<sup>10,31</sup> Recently, our group published an MRI study showing that ‘gliosis



**Figure 4** Graphical summary of the differences between hippocampal I<sup>2</sup>GO and HS. I<sup>2</sup>GO constitutes a distinct MTL syndrome with characteristic clinical and pathological features. I<sup>2</sup>GO is less amendable by surgery and bears a greater hazard for postoperative neuropsychological deterioration. 'Gliosis only', the neuropathological hallmark of I<sup>2</sup>GO, shows a unique transcriptional signature marked by an astrocyte-mediated chronic inflammation pattern.

only' reveals characteristic MRI features discriminating it from HS.<sup>10</sup> Therefore, we used the same MRI criteria to evaluate a representative subset of MRI images of patients with 'gliosis only' and HS. The results supported the previous results, showing that characteristic of HS features (reduction in hippocampal volume, complete loss of internal hippocampal structure and the marked increase in T<sub>2</sub>-signal intensity) were absent in most I<sup>2</sup>GO cases (Supplementary Fig. 3). These findings were further confirmed by a quantitative assessment of hippocampus and amygdala volumes and normalized fluid-attenuated inversion recovery (FLAIR) signal showing significant differences between affected hippocampus and contralateral hippocampus in HS. In contrast, no significant difference could be found between the affected and the contralateral hippocampus in patients with I<sup>2</sup>GO (Supplementary Figs 4 and 5).

### I<sup>2</sup>GO patients have distinct demography and worse seizure and neuropsychological outcome compared to HS patients

Here we argue that I<sup>2</sup>GO neuropathologically hallmarked by 'gliosis only' may represent a distinct disease entity mapping to a characteristic phenotype. Patients with I<sup>2</sup>GO are significantly older than

their HS counterparts, which *per se* excludes the hypothesis that 'gliosis only' is a precursor state of HS.

Patients with I<sup>2</sup>GO tended to show less and more diffuse cognitive impairments prior to surgery compared to HS. Verbal and non-verbal memory more frequently declined in this group after surgery. Memory performance in TLE very much depends on the structural and functional integrity of the hippocampus.<sup>32</sup> The finding of more diffuse and less severe memory impairment in I<sup>2</sup>GO would be in line with the assumption of a less severe, more diffuse and more bilateral hippocampal pathology. This puts this group at a greater risk of postoperative decline.<sup>32</sup>

Together with the fact that I<sup>2</sup>GO patients are less likely to become seizure free, they are at a higher risk of becoming so-called 'double losers', i.e. not becoming seizure free and also experiencing memory loss.

### I<sup>2</sup>GO epileptogenicity based on astrocytic induced inflammation without neuronal cell loss

The findings so far suggest that in I<sup>2</sup>GO, different from HS, a less severe, more diffuse and widespread pathology is being found, implicating a more widespread epileptogenic zone with greater risk for

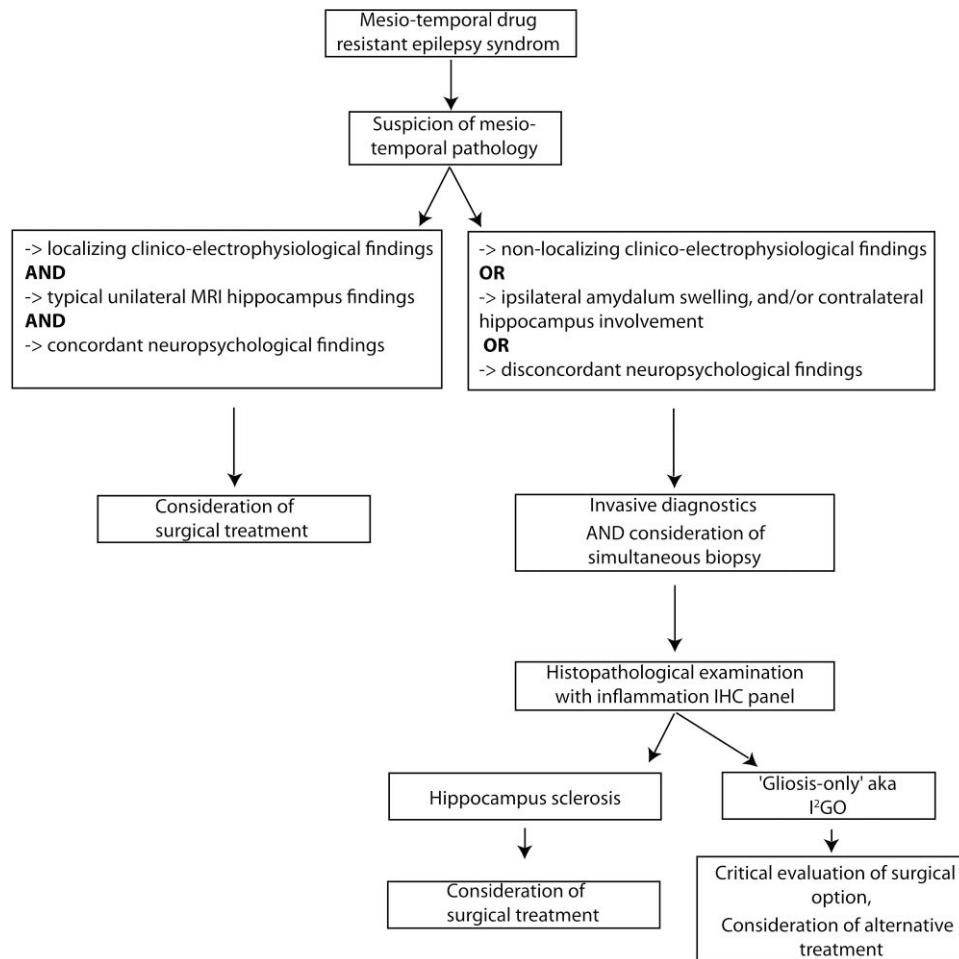


Figure 5 Decision pathway considering the diagnosis of I<sup>2</sup>GO as part of the presurgical diagnostics.

seizure relapse after standard surgical procedures. Presurgical analyses as well as neuropsychological focus mapping have clearly ruled out epileptogenic network activity outside the hippocampal formation as the seizure onset zone in the present patients. If a suspicion of extratemporal or even temporal lateral focus was raised during the preoperative evaluation, patients were suggested for invasive diagnostic tests aiming to localize the focus precisely. Therefore, the observed gliosis pattern constitutes an intrinsic pathological aspect of the epileptogenic focus. In this respect, it is remarkable that the comparison of transcriptional programmes between both entities reveals a first hint of potential innate non-adaptive inflammatory alterations suggesting a distinct pathomechanism in I<sup>2</sup>GO. Pathogenetically, the molecular profile of the I<sup>2</sup>GO hippocampi uncovers a strongly inflammatory microenvironment evoked by the reactively transformed astroglial cell component that is therefore well suited to fundamentally contribute to epileptogenesis of the affected hippocampal network. We observed a distinct activation of the complement pathway associated with inflammatory adaptation of astrocytes similar to those observed in inflammatory diseases such as Morbus Alzheimer or encephalomyelitis disseminata (Supplementary Fig. 1). Further investigation is required to corroborate these initial suspicions. In addition, the frequent bilateral occurrence of I<sup>2</sup>GO underpinning these systemic inflammatory changes may be involved in disease pathogenesis. Thus, we assume that the reactive astrocytes in I<sup>2</sup>GO drive aberrant

neuronal plasticity, which is constituted by an astrocyte-neuron signalling cascade resulting in persistent functional modification of hippocampal excitatory synapses.<sup>33</sup>

In our work, we linked inflammatory transcriptional programmes to patients with a significantly worse clinical outcome in terms of seizure freedom and neuropsychology, although the causality was not proven and need further experimental validations. Other authors have demonstrated a neurotoxic effect of reactive astrocytes on the hippocampus in murine models. Although the definite mechanism remains to be further examined, it can be assumed that alterations in neuronal synapses are provoked by a loss of homeostatic functions and release of inflammatory cytokines.<sup>33</sup> Thus, our results reveal abundant transcriptional differences between HS and I<sup>2</sup>GO, suggesting two different disease entities. The neuroinflammatory transcriptional signature of I<sup>2</sup>GO suggests more global and vaster pathomechanisms involved in epilepsy development, which may be less amendable by surgical treatment. In accordance, the clinical differences between both groups supported the transcriptional results.

### Clinical implications

Beside all other differences, it is the significantly worse post-operative seizure outcome combined with the higher risk for neuropsychological deterioration after surgery that urges a direct clinical consequence. Figure 5 proposes a decision-making flow chart,

which considers the diagnosis of ‘gliosis only’ before performing a resection of mesial-temporal structures. For this purpose, any inconclusive non-invasive findings during the preoperative diagnostics of MTLE, which lead to the indication of invasive electrode implantation, should be critically evaluated under the spotlight of the current results. In particular, in patients showing ipsilateral amygdala swelling and/or contralateral hippocampus involvement as well as less severe and more diffuse preoperative neuropsychological impairment, a biopsy of a tissue sample to exclude possible ‘gliosis only’ together with invasive EEG, should be taken into consideration. The biopsy samples are mainly encountering hippocampal tissue (CA1, CA3 and CA4) that reflect the maximal cellular compositional—and therefore—transcriptional profiling differences between I<sup>2</sup>GO and HS. Therefore, it may be clearly anticipated that the neuropathological in concert with the mRNA signature analyses in biopsy specimens will successfully differentiate I<sup>2</sup>GO from HS. Consequently, if ‘gliosis only’ is diagnosed, further conservative treatment options prior to surgery should be critically discussed with the patients and their caregivers.

This algorithm should not be interpreted as scepticism towards surgical treatment of patients with MTLE, but rather as ‘change of paradigm’ with ‘red flags’ pointing at important implications for the consultation and treatment of patients with one of the most common epilepsy types. Even though most patients with TLE can be classified according to the established syndromic groups, there are still subfractions of patients with TLE, where the pathology and pathogenesis are still difficult to define, and conversely, also defining clear and unequivocal clinic-electrophysiological/MRI profiling features remains somewhat vague. Especially in ambiguous cases, the use of radiologic biomarkers including quantitative volumetric analysis, estimation of T<sub>2</sub> relaxation time through the hippocampus or assessment of normalized FLAIR signal may help to clarify the diagnosis of I<sup>2</sup>GO, thus supporting the decision-making process during routine preoperative work-up.<sup>34,35</sup> Concerning the topic of TLE, this e.g. holds true for grey-white matter blurring.<sup>36</sup> However, molecular genetic studies may fundamentally improve the categorization of patients with so far poorly defined epilepsy and support the improved definition of epilepsy-associated syndromes. The finding of abundant SLC35A2 brain mosaicism in mild malformation of cortical development with oligodendroglial hyperplasia in epilepsy may be regarded as a striking example in this context.<sup>37</sup> Our present paper clearly shows that the integration of neuropathological features with a transcriptomic signature fundamentally fosters the definition of an epilepsy syndrome (I<sup>2</sup>GO, as we suggest here) overcoming the rather descriptive ‘no-HS, ‘gliosis only’ in a TLE patient group that has so far been difficult to define by integrated clinico-electrophysiological/MRI and histological characteristics. I<sup>2</sup>GO is less curable by surgery. Therefore, adequate treatment requires a revision of the current MTLE diagnostic and clinical practice algorithm and the consideration of novel pharmacotherapies (e.g. fingolimod)<sup>38</sup> in the future.

## Acknowledgements

BioRender (www.biorender.com) was used to create figure illustrations. This work was supported in part by BMBF (German Ministry of Education and Research, project number 031L0260B, D.H.H. and D.D.), DFG to A.J.B. [SFB 1089 (D10), FOR 2715 (P7)], A.R.’s significant contribution to this paper will in part fulfil requirements of her MD thesis (supported by the Else Kröner-Fresenius Graduate School ‘Neuroimmunology’), the BONFOR programme of the University of Bonn Medical Center (internal UKB ID: O-126.0046) and Graduierten-

Stipendium der Novartis-Stiftung für Therapeutische-Forschung to A.G. J.T. has contributed substantially to the study design, data acquisition/analysis and interpretation of neuropsychological data as part of her PhD. J.T. was involved in drafting and revising the article.

## Funding

No funding was received towards this work.

## Competing interests

The authors report no competing interests.

## Supplementary material

Supplementary material is available at *Brain* online.

## References

- Blumcke I, Spreafico R, Haaker G, et al. Histopathological findings in brain tissue obtained during epilepsy surgery. *N Engl J Med.* 2017;377:1648–1656.
- Wiebe S, Blume WT, Girvin JP, Eliasziw M. A randomized, controlled trial of surgery for temporal-lobe epilepsy. *N Engl J Med.* 2001;345:311–318.
- Blümcke I, Thom M, Aronica E, et al. International consensus classification of hippocampal sclerosis in temporal lobe epilepsy: A task force report from the ILAE commission on diagnostic methods. *Epilepsia.* 2013;54:1315–1329.
- Blümcke I, Kistner I, Clusmann H, et al. Towards a clinicopathological classification of granule cell dispersion in human mesial temporal lobe epilepsies. *Acta Neuropathol (Berl).* 2009; 117:535–544.
- Lamberink HJ, Otte WM, Blümcke I, et al. Seizure outcome and use of antiepileptic drugs after epilepsy surgery according to histopathological diagnosis: a retrospective multicentre cohort study. *Lancet Neurol.* 2020;19:748–757.
- Leal B, Chaves J, Carvalho C, et al. Brain expression of inflammatory mediators in mesial temporal lobe epilepsy patients. *J Neuroimmunol.* 2017;313:82–88.
- Zhu Q, Wang L, Zhang Y, et al. Increased expression of DNA methyltransferase 1 and 3a in human temporal lobe epilepsy. *J Mol Neurosci MN.* 2012;46:420–426.
- Xi ZQ, Xiao F, Yuan J, et al. Gene expression analysis on anterior temporal neocortex of patients with intractable epilepsy. *Synapse.* 2009;63:1017–1028.
- Burkholder DB, Sulc V, Hoffman EM, et al. Interictal scalp electroencephalography and intraoperative electrocorticography in magnetic resonance imaging-negative temporal lobe epilepsy surgery. *JAMA Neurol.* 2014;71:702–709.
- Hattingen E, Enkirch SJSJ, Jurcoane A, et al. Hippocampal ‘gliosis only’ on MR imaging represents a distinct entity in epilepsy patients. *Neuroradiology.* 2018;60:161–168.
- Devinsky O, Vezzani A, Najjar S, De Lanerolle NC, Rogawski MA. Glia and epilepsy: Excitability and inflammation. *Trends Neurosci.* 2013;36:174–184.
- Thom M. Review: hippocampal sclerosis in epilepsy: A neuropathology review. *Neuropathol Appl Neurobiol.* 2014;40:520–543.
- Kral T, Clusmann H, Urbach H, et al. Preoperative evaluation for epilepsy surgery (Bonn Algorithm). *Zentralblatt Für Neurochir.* 2002;63:106–110.



14. The Jamovi Project (2021). Jamovi. (Version 2.0) [Computer Software]. Retrieved from <https://www.jamovi.org>
15. Campos AR, Clusmann H, von Lehe MM, et al. Simple and complex dysembryoplastic neuroepithelial tumors (DNT) variants: clinical profile, MRI, and histopathology. *Neuroradiology*. 2009; 51:433–443.
16. Henrik Heiland D, Ravi VM, Behringer SP, et al. Tumor-associated reactive astrocytes aid the evolution of immunosuppressive environment in glioblastoma. *Nat Commun*. 2019;10:2541.
17. Grote A, Witt JAJA, Surges R, et al. A second chance-reoperation in patients with failed surgery for intractable epilepsy: Long-term outcome, neuropsychology and complications. *J Neurol Neurosurg Psychiatry*. 2016;87:379–385.
18. Gleissner U, Helmstaedter C, Schramm J, Elger CE. Memory outcome after selective amygdalohippocampectomy in patients with temporal lobe epilepsy: One-year follow-up. *Epilepsia*. 2004;45:960–962.
19. Helmstaedter C, Elger CE. Cognitive consequences of two-thirds anterior temporal lobectomy on verbal memory in 144 patients: A three-month follow-up study. *Epilepsia*. 1996;37:171–180.
20. Helmstaedter C, Grunwald T, Lehnertz K, Gleißner U, Elger CE. Differential involvement of left temporolateral and temporomesial structures in verbal declarative learning and memory: Evidence from temporal lobe epilepsy. *Brain Cogn*. 1997;35:110–131.
21. Helmstaedter C, Pohl C, Hufnagel A, Elger CE. Visual learning deficits in nonresected patients with right temporal lobe epilepsy. *Cortex*. 1991;27:547–555.
22. Helmstaedter C, Richter S, Röske S, Oltmanns F, Schramm J, Lehmann TN. Differential effects of temporal pole resection with amygdalohippocampectomy versus selective amygdalohippocampectomy on material-specific memory in patients with mesial temporal lobe epilepsy. *Epilepsia*. 2008;49:88–97.
23. Helmstaedter C, Lendt M, Lux S. *Verbaler Lern- und Merkfähigkeitstest*. Beltz Test; 2001.
24. Helmstaedter C, Stefan H, Witt JA. Quality of life in patients with partial-onset seizures under adjunctive therapy with zonisamide: Results from a prospective non-interventional surveillance study. *Epileptic Disord Int Epilepsy J Videotape*. 2011;13: 263–276.
25. Witt JA, Helmstaedter C. [Neuropsychology in epilepsy]. *Fortschr Neurol Psychiatr*. 2009;77:691–698.
26. Reyes A, Kaestner E, Ferguson L, et al. Cognitive phenotypes in temporal lobe epilepsy utilizing data- and clinically driven approaches: Moving toward a new taxonomy. *Epilepsia*. 2020;61: 1211–1220.
27. Hermann B, Conant LL, Cook CJ, et al. Network, clinical and sociodemographic features of cognitive phenotypes in temporal lobe epilepsy. *NeuroImage Clin*. 2020;27:102341.
28. Clusmann H, Schramm J, Kral T, et al. Prognostic factors and outcome after different types of resection for temporal lobe epilepsy. *J Neurosurg*. 2002;97:1131–1141.
29. Soeder BM, Gleissner U, Urbach H, et al. Causes, presentation and outcome of lesional adult onset mediotemporal lobe epilepsy. *J Neurol Neurosurg Psychiatry*. 2009;80:894–899.
30. Graus F, Titulaer MJ, Balu R, et al. A clinical approach to diagnosis of autoimmune encephalitis. *Lancet Neurol*. 2016;15:391–404.
31. Vaughan DN, Rayner G, Tailby C, Jackson GD. MRI-negative temporal lobe epilepsy. *Neurology*. 2016;87:1934–1942.
32. Witt JA, Coras R, Schramm J, et al. Relevance of hippocampal integrity for memory outcome after surgical treatment of mesial temporal lobe epilepsy. *J Neurol*. 2015;262:2214–2224.
33. Habbas S, Santello M, Becker D, et al. Neuroinflammatory TNF $\alpha$  impairs memory via astrocyte signaling. *Cell*. 2015;163:1730–1741.
34. Huppertz HJ, Wagner J, Weber B, House P, Urbach H. Automated quantitative FLAIR analysis in hippocampal sclerosis. *Epilepsy Res*. 2011;97:146–156.
35. Focke NK, Bonelli SB, Yogarajah M, Scott C, Symms MR, Duncan JS. Automated normalized FLAIR imaging in MRI-negative patients with refractory focal epilepsy. *Epilepsia*. 2009;50:1484–1490.
36. Demerath T, Donkels C, Reisert M, et al. Gray-white matter blurring of the temporal pole associated with hippocampal sclerosis: a microstructural study involving 3 T MRI and ultrastructural histopathology. *Cereb Cortex*. 2022;32:1882–1893.
37. Bonduelle T, Hartlieb T, Baldassari S, et al. Frequent SLC35A2 brain mosaicism in mild malformation of cortical development with oligodendroglial hyperplasia in epilepsy (MOGHE). *Acta Neuropathol Commun*. 2021;9:3.
38. Pitsch J, Kuehn JC, Gnatkovsky V, et al. Anti-epileptogenic and anti-convulsive effects of fingolimod in experimental temporal lobe epilepsy. *Mol Neurobiol*. 2019;56:1825–1840.

### 3.3 Publication 3: Preoperative and postoperative memory in epilepsy patients with 'gliosis only' versus hippocampal sclerosis: a matched case-control study

Original research

# Preoperative and postoperative memory in epilepsy patients with 'gliosis only' versus hippocampal sclerosis: a matched case–control study

Julia Taube <sup>1</sup>, Juri-Alexander Witt,<sup>1</sup> Alexander Grote,<sup>2</sup> Daniel Delev,<sup>3</sup> Jonas Enkirch,<sup>4</sup> Elke Hattingen,<sup>5</sup> Albert J Becker,<sup>6</sup> Christian Erich Elger,<sup>1</sup> Christoph Helmstaedter<sup>1</sup>

<sup>1</sup>Department of Epileptology, University Hospital Bonn, Bonn, Germany

<sup>2</sup>Department of Neurosurgery, University of Marburg, Marburg, Germany

<sup>3</sup>Clinic for Neurosurgery, University Medical Center Aachen, Aachen, Germany

<sup>4</sup>Department of Neuroradiology, University Hospital Bonn, Bonn, Germany

<sup>5</sup>Institute of Neuroradiology, University Hospital Frankfurt, Goethe-University, Frankfurt am Main, Germany

<sup>6</sup>Institute of Neuropathology, Section for Translational Epilepsy Research, University of Bonn, Medical Faculty, Bonn, Germany

## Correspondence to

Julia Taube, Department of Epileptology, University Hospital Bonn, 53127 Bonn, Germany; Julia.Taube@ukbonn.de

Received 9 March 2022

Accepted 14 August 2022

Published Online First 25 August 2022

## ABSTRACT

**Background** Gliosis only (GO) and hippocampal sclerosis (HS) are distinct histopathological entities in mesial temporal lobe epilepsy. This study explores whether this distinction also exists on a functional level when evaluating pre- and postoperative memory.

**Methods** Using a retrospective matched case–control study design, we analysed verbal and visual memory performance in 49 patients with GO and 49 patients with HS before and one year after elective surgery.

**Results** Clinical differences were evident with a later age at seizure onset ( $18 \pm 12$  vs  $12 \pm 9$  years) and fewer postoperative seizure-free patients in the GO group (63% vs 82%). Preoperatively, group and individual-level data demonstrated that memory impairments were less frequent, less severe and relatively non-specific in patients with GO compared with HS. Postoperatively, verbal memory declined in both groups, particularly after left-sided resections, with more significant losses in patients with GO. Factoring in floor effects, GO was also associated with more significant visual memory loss, particularly after left resections.

**Conclusions** Compared with HS, GO is characterised by (1) a later onset of epilepsy, (2) less pronounced and more non-specific memory impairments before surgery, (3) a less successful surgical outcome and (4) a more significant memory decline after surgery. Overall, our results regarding cognition provide further evidence that GO and HS are distinct clinical entities. Functional integrity of the hippocampus appears higher in GO, as indicated by a better preoperative memory performance and worse memory outcome after surgery. The different risk–benefit ratios should be considered during presurgical patient counselling.

## INTRODUCTION

Hippocampal sclerosis (HS) is the most common histopathological finding underlying drug-resistant mesial temporal lobe epilepsy (mTLE) and has been intensively investigated regarding clinical characteristics, pathogenesis, epileptogenesis and treatment outcome.<sup>1</sup> Notable characteristics of HS are segmental pyramidal cell loss and reactive astrogliosis, described in 54% of hippocampal specimens.<sup>2</sup>

No HS with gliosis only (GO) is characterised by mild or no neuronal cell loss with reactive astrogliosis and is found in 20% of the resected specimens.<sup>2–4</sup> GO was only recently described as a histopathological entity distinct from HS in the

## WHAT IS ALREADY KNOWN ON THIS TOPIC

⇒ Gliosis only (GO) and hippocampal sclerosis (HS) represent two distinct pathologies in refractory temporal lobe epilepsy with different clinical features, such as a later epilepsy onset, bilateral MRI abnormalities and worse seizure outcome after surgery in GO. However, associated functional consequences as revealed by preoperative and postoperative memory in patients with GO have not yet been addressed.

## WHAT THIS STUDY ADDS

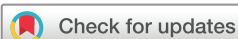⇒ Our results confirm that GO and HS are different clinical entities not only on a histopathological but on a functional level. GO is characterised by less severe and more non-specific memory deficits before surgery. This puts them at risk for postoperative memory decline compared to patients with HS, who show greater memory problems before surgery.

## HOW THIS STUDY MIGHT AFFECT RESEARCH, PRACTICE OR POLICY

⇒ Our findings can help with surgical decision making in individual patient care, and they may stimulate further research into the aetiology of gliosis as a disjunct pathological entity from HS.

consensus classification provided by the International League Against Epilepsy (ILAE), emphasising that reactive astrocytes play a substantial role in epileptogenesis and seizure spreading, even in the almost complete absence of neuronal cell loss.<sup>4</sup> Reactive astrocytes are heterogeneous and involve poorly understood epileptogenic processes in GO with associated structural and functional changes and different implications for diagnosis, treatment and outcome. Chronically activated astrocytes are linked to the release of proinflammatory mediators in the brain, contributing to the pathogenesis of seizures, epilepsy and possibly cognition.<sup>4</sup>

MRI allows for a differentiation of HS and GO before surgery. HS is characterised by a reduced ipsilateral volume (hippocampal atrophy), an increased T<sub>2</sub>-weighted/T<sub>2</sub>-fluid-attenuated inversion recovery (FLAIR) signal and a loss of internal architecture.<sup>3</sup> While a narrower pyramidal cell layer in the cornu ammonis area 1 corresponding to the degree of atrophy in hippocampal specimens has



© Author(s) (or their employer(s)) 2022. No commercial re-use. See rights and permissions. Published by BMJ.

**To cite:** Taube J, Witt J-A, Grote A, et al. *J Neurol Neurosurg Psychiatry* 2022;**93**:1202–1208.

been described in HS patients, it was not observed in GO.<sup>5</sup> GO comprises larger ipsilateral hippocampal volumes<sup>6</sup> and fewer ipsilateral signal intensity alterations,<sup>3</sup> which suggests that the structural hippocampal integrity in GO is overall better preserved compared with HS. Unlike HS, the contralateral hippocampus in GO seems more frequently affected, as depicted by contralateral T<sub>2</sub>-weighted signal intensity changes, implying a bilateral hippocampal involvement. As a result, GO has been referred to as a network disorder associated with possible inflammatory pathomechanisms.<sup>3,7</sup> In line with this argument, GO is associated with a later onset of epilepsy and lower seizure freedom rates after surgery.<sup>8</sup>

Functional differences between GO and HS have not yet been addressed but would be relevant for patients' presurgical evaluation, clinical decision making and counselling. The previously demonstrated interrelation of hippocampal integrity, preoperative episodic memory performance and postoperative outcome in HS provides the theoretical framework for our hypotheses.<sup>9–11</sup> Verbal memory impairments are most consistently found in left, while visual memory impairments appear less strictly related to right mTLE.<sup>12</sup> The structural hippocampal integrity, as assessed by hippocampal cell densities, correlates with poor preoperative memory performance.<sup>9,13</sup> Verbal memory decline can be expected in 44% and 21% of patients after left and right temporal lobe surgery (TLS).<sup>14</sup> Visual memory decline following left or right TLS can occur in up to 20% of the patients.<sup>14,15</sup> A major predictor of postoperative deterioration of memory following TLS is the preoperative structural and functional status of the ipsilateral hippocampus to be resected.<sup>9,10,16</sup> Based on this structural and functional relation between hippocampal pathology and memory in mTLE, we hypothesised that GO patients should show milder, more non-specific and bilateral memory impairments before surgery than patients with HS.<sup>8,15,17</sup> In addition, due to the suspected baseline differences, GO patients should be at greater risk of postoperative memory decline than patients with HS.

## METHODS

### Participants

We retrospectively analysed 49 patients with GO (right TLE: n=30) and 49 with HS (right TLE: n=29) (see [table 1](#)). All patients underwent surgery for refractory mTLE at the level 4 epilepsy centre at the University Hospital in Bonn, Germany, between 1989 and 2012. Histopathological analyses of the resected specimens followed the ILAE criteria. The diagnosis of mTLE was based on seizure semiology, clinical history, prolonged videoelectroencephalography monitoring, neuroimaging and neuropsychological assessment. We evaluated seizure freedom based on information obtained at the postoperative neuropsychological follow-up assessment one year after surgery. Freedom from seizures corresponded to category Ia in the Engel classification, that is, completely seizure-free since surgery. We only included histopathologically confirmed GO or HS patients and no other pathology or epileptogenic lesion.

Further inclusion criteria comprised no previous invasive treatments (eg, surgery, radiotherapy), age >16 years and complete neuropsychological data sets. Patients were matched for the side of surgery and surgical procedure to control for differential effects of the extent of resection. A subset of patients has already been published in an imaging study by Hattingen *et al.*<sup>3</sup>

**Table 1** Patient demographics and clinical characteristics

Pathology n=	GO 49	HS 49	P value
Sex (female)	59%	41%	ns
Age at surgery (years)	35±11	37±10	ns
Age at onset (years)	18±12	12±9	<0.05
Duration (years)	17±10	24±12	<0.05
Intelligence (IQ)	102±13	103±12	ns
MRI	44	37	
Positive/negative	18/26	27/10	<0.05
Unilateral/bilateral	15/3	23/4	ns
Type of surgery			
tsAH	55%	59%	ns
ATL	45%	41%	ns
Side of surgery (right)	61%	59%	ns
Preoperative seizure frequency (per month)	10±25	6±11	ns
Seizure outcome (Engel Ia/ILAE Ia)	63%	82%	<0.05
Preoperative number of ASM	2±0.87	2±0.76	ns
Change in no of ASM	-0.24±0.98	-0.50±0.82	ns

ASM, antiseizure medication; ATL, anterior temporal lobectomy; GO, gliosis only; HS, hippocampal sclerosis; ILAE, International League Against Epilepsy; ns, no significant difference; tsAH, trans-sylvian selective amygdalohippocampectomy.

### Neuropsychological assessment

Standardised neuropsychological assessment was conducted before and one year after surgery. The assessment focused on the evaluation of material-specific episodic memory functions. The Verbaler Lern- und Merkfähigkeitstest (VLMT), a German adaptation of the Rey Auditorial Verbal Learning Test, was administered to assess verbal learning and memory. The VLMT is the most frequently used verbal learning and memory test in German-speaking epilepsy centres.<sup>18</sup> Patients had to learn a list of 15 words in 5 consecutive trials, followed by an interference trial, an immediate recall after interference, a delayed recall and a recognition trial.<sup>19,20</sup> The VLMT is sensitive to left temporal lobe dysfunction, left mesial temporal pathology and left-sided TLS.<sup>11,21–23</sup>

For visual learning and memory assessment, the revised Diagnostikum für Cerebralschädigung (DCS-R) was administered.<sup>12,24</sup> Patients had to learn nine different designs, each composed of five lines of equal length, over five consecutive trials. A delayed recognition trial followed learning. The DCS-R is sensitive to right temporal lobe dysfunction, right mesial temporal pathology and right-sided TLS.<sup>12,25–27</sup>

Parallel versions of the memory tests were used to minimise practice effects.

Determination of language dominance was performed by either the intracarotid amobarbital procedure, language functional MRI or the functional transcranial Doppler sonography. Furthermore, we used atypical hand dominance in left mTLE as a marker for atypical hemispheric dominance.

Intelligence was estimated using a German vocabulary test (Mehrfachwahl-Wortschatz-Intelligenztest),<sup>28</sup> which reflects education levels and is a good estimator for crystallised intelligence and premorbid intellectual functioning.

All raw scores have been transformed into standardised scores (mean=100; SD=10). Age norms are based on the data from 488 healthy controls. Reliable change indices (RCIs) are derived from a subset of 100–142 healthy controls with repeated assessment using parallelized versions. Patient norms and RCIs are based on the data from 661 surgically treated TLE patients at our centre including all types of surgery.



### Statistical analysis

Clinical patient characteristics and demographics have been evaluated with independent t-tests,  $\chi^2$  tests of independence and Fisher's exact tests. Preoperative performance differences between the two pathology groups have been investigated via analysis of covariance with the surgical side as the independent variable and seizure onset as a covariate. We also performed  $\chi^2$  tests of independence for pathology and lateralisation of epilepsy to assess individual impairments before surgery.

We calculated the frequencies of atypical memory profiles for each group, which were defined as: (1) performance in verbal or visual memory is classified as unimpaired; (2) performance in both verbal and visual memory was impaired (bilateral memory impairments) or (3) there is a selective memory deficit pointing to the side contralateral to the primary focus.

Preoperative to postoperative changes in memory performance were analysed on a group level with repeated-measures (rm) analysis of variances with surgery as the within-subjects factor. Between-subjects factors were pathology and surgical side. We included the onset of epilepsy and postoperative seizure freedom as a covariate. The rm analyses have been conducted with and without the covariates.

To evaluate significant intraindividual changes that might be masked in group analyses by averaging the results of patients who improved, declined and showed no change, we subtracted the preoperative from the postoperative raw score, that is, positive values indicate improvement and negative values indicate a decline. The postoperative change for each patient was classified into three categories (improvement, deterioration and no change) based on practice-corrected RCIs (with a CI of 90%). We performed  $\chi^2$  tests of independence for pathology and side of surgery.

To evaluate the clinical significance of memory losses after surgery, we calculated the average losses in the different memory parameters from 600 to 661 surgically treated TLE patients at our centre. Based on 1-year postoperative follow-up assessments, RCIs (with a CI of 90%) were calculated. We then identified patients with larger-than-average memory decline after surgery, that is, a patient's drop in memory performance was significantly larger than the average drop recorded in the TLE reference cohort. Finally, we calculated Odds Ratios for the two pathology groups.

Additionally, we considered floor effects in visual memory analysis, as they were observed in 28% of patients, evenly distributed across the two groups. A floor effect occurs when a patient performs so poorly on a test that a decline cannot be

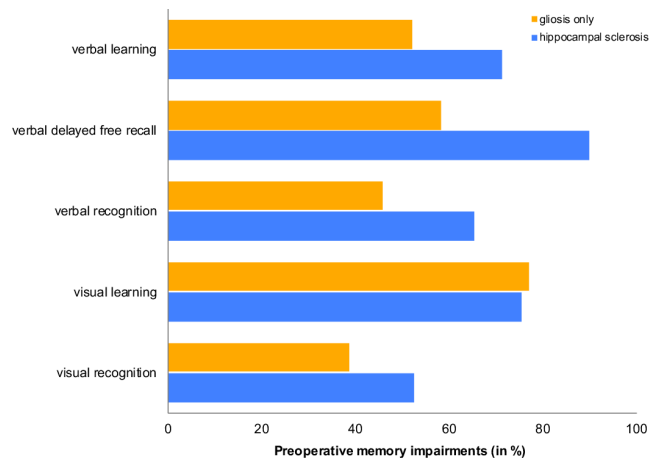
reliably measured, that is, patients with preoperative scores smaller than the RCIs.

We used an alpha level of 0.05 for all statistical tests. Effect size is measured by partial eta square ( $\eta^2$ ).  $\eta^2=0.01$  indicates a small effect,  $\eta^2=0.06$  indicates a medium effect and  $\eta^2=0.14$  indicates a large effect. All analyses have been conducted in IBM SPSS V.25 and jamovi V.2.2.2.

## RESULTS

### Clinical characteristics

The study sample's demographic and clinical characteristics are given in table 1. Forty-three per cent of the patients underwent anterior temporal lobectomy (ATL), and 57% underwent trans-sylvian selective amygdalohippocampectomy (tsAH). There was no significant difference between ATL and tsAH regarding seizure freedom,  $F(1,98)=1.11$ ,  $p=0.30$ ,  $\eta^2=0.01$ . The groups differed significantly regarding age at epilepsy onset ( $t(96)=2.52$ ,  $p=0.01$ ), duration of epilepsy ( $t(95)=-3.24$ ,  $p<0.01$ ) and the number of MRI-negative cases ( $\chi^2(1)=8.37$ ,  $p<0.01$ ). GO was associated with later epilepsy onset, shorter duration and more frequent MRI-negative cases. The groups did not differ significantly regarding intelligence.



**Figure 1** Preoperative frequency of memory impairments (displayed as percentages). Standardised preoperative memory scores  $<90$  were classified as impaired.

**Table 2** Preoperative and postoperative memory performance (displayed as standard values,  $M=100$ ,  $SD=10$ ).

		Left		Right	
		pre mean (SD)	post mean (SD)	pre mean (SD)	post mean (SD)
Verbal learning	GO	90.5 (10.9)	79.3 (10.4)	89.0 (11.75)	87.1 (13.1)
	HS	83.3 (7.4)	80.0 (9.6)	86.3 (9.7)	87.2 (15.0)
Verbal delayed free recall	GO	84.4 (16.9)	72.6 (7.8)	86.2 (15.9)	86.0 (15.1)
	HS	75.7 (9.4)	70.3 (9.1)	82.8 (12.2)	82.1 (13.6)
Verbal recognition	GO	91.8 (20.5)	73.2 (19.9)	83.7 (21.1)	83.4 (31.7)
	HS	75.1 (24.9)	69.4 (20.8)	85.5 (15.8)	78.7 (25.6)
Visual learning	GO	84.0 (13.6)	76.8 (10.7)	80.4 (10.1)	78.1 (8.7)
	HS	85.4 (10.6)	85.5 (10.7)	80.1 (9.2)	78.8 (9.4)
Visual recognition	GO	85.9 (19.8)	83.7 (19.2)	89.2 (11.2)	82.5 (16.0)
	HS	95.4 (10.6)	97.3 (12.1)	81.6 (13.4)	82.9 (16.0)

GO, gliosis only; HS, hippocampal sclerosis.

### Preoperative memory

Patients with GO and HS showed impairments in almost all verbal and visual memory parameters (see table 2). Overall, visual learning was most frequently impaired, followed by verbal learning and delayed verbal recall (see figure 1). Performance was unimpaired in 19% of the GO patients and only 4% of the HS patients.

Group-level analysis indicated that GO patients performed better in verbal learning ( $F(1,91)=4.98$ ,  $p=0.028$ ,  $\eta^2=0.05$ ), and verbal delayed free recall ( $F(1,91)=4.12$ ,  $p=0.04$ ,  $\eta^2=0.04$ ). Visual learning was significantly more impaired in right than left mTLE ( $F(1,91)=4.31$ ,  $p=0.04$ ,  $\eta^2=0.04$ ). Interaction effects between lateralisation and pathology were found for verbal ( $F(1,91)=3.77$ ,  $p=0.05$ ,  $\eta^2=0.04$ ) and visual recognition ( $F(1,76)=9.26$ ,  $p=0.01$ ,  $\eta^2=0.09$ ), indicating that verbal recognition was most impaired in left HS and visual recognition in right HS. The age at onset of epilepsy did not significantly affect the preoperative performance ( $p>0.05$ ).

Consistent with the group-level analysis, individual-level analyses revealed that verbal learning, verbal delayed free recall and verbal recognition were more frequently impaired in HS than in GO in left mTLE (Fisher's exact test, each  $p<0.01$ ). Also, visual recognition (Fisher's exact test,  $p<0.01$ ) was more frequently impaired in right HS. Most patients showed deficits in visual learning without significant group differences ( $p>0.05$ ).

Looking into individual atypical memory profiles, the performance of patients with GO is significantly more often unimpaired (14%) than in patients with HS (6%), but there were no significant differences regarding bilateral or contralateral impairment patterns (Fisher's exact t-test,  $p>.05$ ).

### Preoperative to postoperative memory change

Seizure freedom was reached in only 63% of the patients with GO but in 82% of patients with HS ( $\chi^2(1)=4.14$ ,  $p=0.04$ ). Overall, verbal memory declined more frequently and severely than visual memory in both groups (see table 2), with more pronounced effects in patients with GO, especially following left TLS. The frequencies of intraindividual losses and gains following left and right TLS are presented in figure 2.

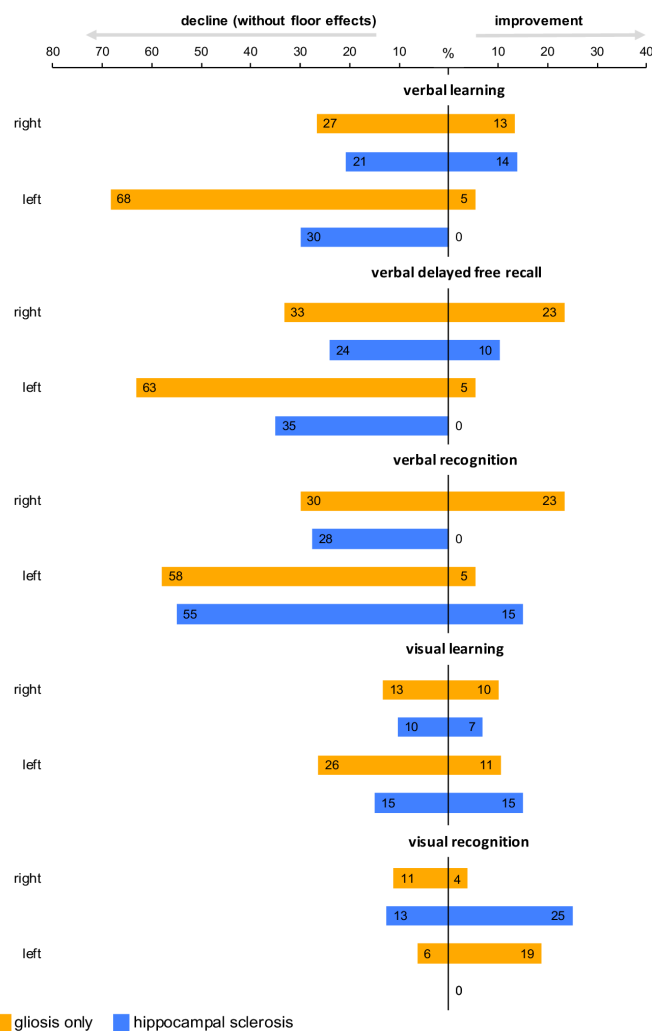
### Verbal memory

Learning ( $F(1,87)=8.53$ ,  $p=0.004$ ,  $\eta^2=0.003$ ) and delayed free recall of verbal information ( $F(1,87)=5.86$ ,  $p=0.02$ ,  $\eta^2=0.002$ ) significantly declined after left TLS in both pathology groups. In addition, postoperative loss in learning performance was marginally greater in patients with GO ( $F(1,87)=4.30$ ,  $p=0.04$ ,  $\eta^2=0.002$ ; see figure 3), with a tendency of a more pronounced loss after left TLS. Recognition remained unchanged ( $p>0.05$ ). Seizure freedom did not significantly impact other postoperative outcomes ( $p>0.05$ ).

Correspondingly, on an individual level, a decline in verbal learning and recall performance occurred twice as often in GO than in HS following left TLS ( $\chi^2(2)=7.82$ ,  $p=0.02$ ). At the same time, GO was associated with more gains in verbal recognition than HS ( $\chi^2(2)=8.44$ ,  $p=0.01$ ). After right TLS, there was no significant group difference ( $p>0.05$ ). The results remained robust when excluding patients with atypical language dominance.

### Visual memory

To account for floor effects in visual learning ( $p>0.05$ ), data from 28% of the patients were excluded from further analysis.



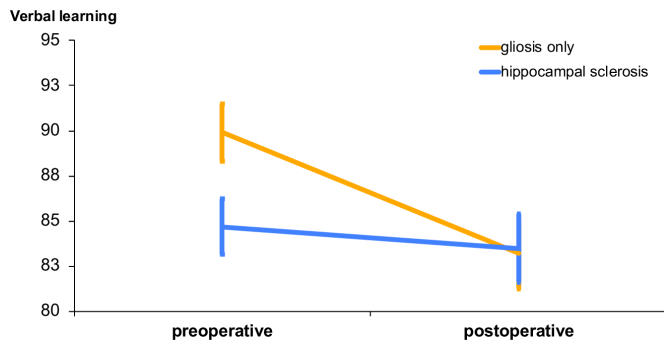
**Figure 2** Intraindividual memory change from preoperative to postoperative assessment (displayed in % of patients who declined (left) or improved (right)). The results of all patients without floor effects are included. The postoperative change was classified into three categories (improvement, deterioration and no change) based on practice-corrected reliable change indices (with a CI of 90%) derived from 100 to 142 reassessed healthy controls.

After left TLS, and on a group level, learning declined significantly more in patients with GO than HS, while losses were comparable following right TLS,  $F(1,63)=4.62$ ,  $p=0.035$ ,  $\eta^2=0.068$ ; see figure 4). Recognition tended to decline only in patients with GO following right TLS ( $p>0.05$ , see table 2). Postoperative seizure freedom did not significantly impact cognitive outcomes ( $p>0.05$ ).

The individual-level analysis confirmed that a deterioration in learning following left TLS was almost twice as likely in GO, though the result failed to reach statistical significance ( $p>0.05$ ). Following right TLS, no statistical significance was found for learning or recognition ( $p>0.05$ ). The results were similar when the analysis was performed without considering floor effects.

### Significance of postoperative memory losses

In both pathology groups, we identified patients with larger-than-average memory losses after surgery (see table 3). However, patients with GO were more likely faced with a loss of performance in verbal and visual memory much larger than the average loss of the TLE cohort (OR=1.61–3.45).



**Figure 3** Verbal learning before and after left TLS (estimated marginal means in standard values,  $M=100$ ,  $SD=10$ ). TLS, temporal lobe surgery.

## DISCUSSION

This study investigated the preoperative memory performance and postoperative memory outcomes in patients with mTLE due to either histopathologically confirmed GO or HS. Following previous studies describing HS and GO as different clinical entities, we analysed potential functional differences based on memory tests sensitive to temporal lobe pathology and the effects of TLS.<sup>11 21–23 26 27</sup>

Recent histopathological analysis indicates that HS is associated with neuronal cell loss and reactive astroglia, while GO is associated with reactive astroglia only and no hippocampal cell loss.<sup>2</sup> Together with imaging studies, which describe less volume loss and fewer signal alterations in the ipsilateral hippocampus in patients with GO, better structural integrity than in HS can be assumed.<sup>3</sup> In addition, imaging data suggest a more bilateral affection in GO.<sup>3</sup> As preoperative performance in mTLE depends on the overall pathological status of the hippocampus, we expected to see mild but less specific memory impairments before surgery in patients with GO versus HS.<sup>11</sup>

Better preoperative performance is a risk factor for cognitive decline. According to the functional adequacy model, postoperative memory loss depends on the tissue's functional integrity to be resected.<sup>15 29</sup> Consequently, better preoperative performance should put these patients at a greater risk for postoperative cognitive decline.

In line with previous reports, significant differences between the two pathology groups were already evident from a clinical perspective. The age of onset was later, and the duration of epilepsy was shorter in GO than in HS. MRI findings were more

**Table 3** Frequency of patients with a larger-than-average memory decline

	GO	HS	OR; 95% CI
Verbal learning	12 (25%)	5 (10%)	2.85; 0.92 to 8.85
Verbal memory	9 (18%)	3 (6%)	3.45; 0.87 to 13.63
Visual learning	9 (25%)	6 (17%)	1.61; 0.51 to 5.13

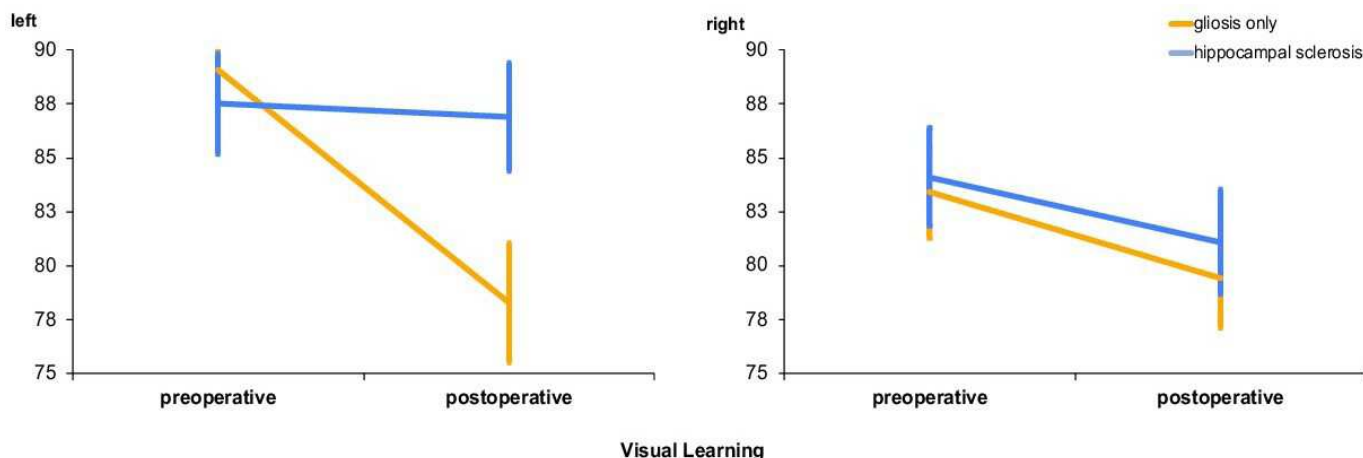
GO, gliosis only; HS, hippocampal sclerosis.

frequently either negative or bilateral in our GO cohort. Our results indicate that GO is a milder but more diffuse pathology than HS, confirming previous research.<sup>3 30</sup> The more diffuse clinical picture likely contributes to the lower postoperative seizure-free rates found in our patients with GO (63% vs 82%).

The groups were matched for the side and surgical procedures, and no differences in sex, intelligence or age at surgery were found. In line with our hypotheses, GO was associated with less frequent, less severe and more non-specific memory impairments than HS before surgery. This result aligns with previously mentioned studies reporting significant correlations between the structural hippocampal integrity and the degree of preoperative memory impairment.<sup>5 10</sup> The memory profiles of the groups primarily differed because of the larger proportion of unimpaired patients in GO. The suggested differences in bilateral or contralateral impairment rates did not reach statistical significance.

The surgical removal of structurally and functionally intact mesial structures results in a higher risk for a more significant loss of memory after surgery.<sup>15 31</sup> Consistent with this, patients with GO experienced a more frequent and severe postoperative decline in verbal and visual memory than patients with HS, especially after left TLS.<sup>32–35</sup> The frequency of decline in GO exceeds the rate previously reported for TLS, i.e. verbal memory deteriorates in 40%–50% after left and 20%–30% after right TLS, while visual memory decline occurs in 20%–30% after left or right TLS.<sup>14 32</sup> Compared to HS, there is a threefold risk in GO patients for a larger-than-average decline in verbal memory and a twofold risk for visual memory, based on our patient norms. The results remained robust when statistically controlling for relevant clinical differences between the groups.<sup>32–35</sup>

The question of when memory decline becomes a disabling complication is a matter of debate.<sup>33</sup> Interindividual differences in daily experiences, activities and demands must be considered when assessing the ecological impact of list learning impairments



**Figure 4** Visual learning before and after TLS (estimated marginal means in standard values,  $M=100$ ,  $SD=10$ ). TLS, temporal lobe surgery.

on everyday memory.<sup>34</sup> However, a recent study found that list learning was highly predictive of how well TLE patients remembered details from a real-life event,<sup>35</sup> that is, incidental learning and memory of materials, concepts, and contents of a 3-hour neuropsychological evaluation 1 week later. A verbal list learning ability one and a half SDs below the normative mean corresponded to a recall of a personal event, which resembled half of what a healthy control could recall. Future studies will have to determine how the extent of postoperative decline impacts the functioning of everyday living.

In conclusion, the histopathological, clinical and neuropsychological features of GO suggest a milder and more diffuse pathology, which has been discussed to possibly be associated with inflammatory processes and chronic astrocytic activation/dysfunction.<sup>3,30</sup> The absent neuronal cell loss and the intact internal architecture found in GO explain the milder memory impairments before surgery in this group.<sup>5</sup> The less distinct memory patterns can be attributed to a more bilateral affection of the hippocampal regions in GO, as suggested by radiological findings.<sup>3</sup>

Noteworthy, this parallels findings in patients with late onset TLE and absent definite structural damage associated with autoimmune-related or inflammatory pathologies. These patients also show less specific memory impairments, implying a bilateral frontolimbic dysfunction rather than a lateralised hippocampal dysfunction.<sup>7,36</sup>

From a clinician's point of view, it would be essential to have indicators for the presence of GO and the increased risk of postoperative memory decline before surgery. First, the described radiological characteristics (bilateral signal intensity changes in T2 FLAIR) and the mild memory impairment may serve as good indicators. Second, even when no MRI indicators are present, we know from MRI-negative and histopathology-negative MTL patients with no to moderate memory impairment, that they are at an exceptional risk to show severe memory decline after surgery.<sup>15</sup>

One question remains unanswered. Assuming that GO is indeed associated with past or ongoing inflammatory processes, is there a higher risk for GO patients to experience progressive memory decline in addition to the postoperative losses? To our knowledge, this question has not yet been addressed separately for patients with GO or HS. However, the histopathological evaluation of resected hippocampal specimens from surgically treated patients with Limbic Encephalitis points to a possible link between long-lasting immune reactions in the MTL, HS and the development of neurodegenerative diseases.<sup>36</sup>

## LIMITATIONS

A limitation of our study is the retrospective study design. However, this allowed us to match the patient groups according to relevant clinical aspects, that is, type and side of surgery. Data on language decline after surgery modulating memory loss could be of interest but were not available for most patients. According to our knowledge, this is the first study to describe distinctive memory profiles of patients suffering from mTLE due to GO compared with HS before and after surgery. Postoperative changes were evaluated on a group and individual level in the largest subset of patients with GO reported to date with relevant clinical information otherwise masked through group data. Furthermore, we employed valid cognitive measures with proven sensitivity to left and right TL pathologies and surgeries.<sup>37</sup> A larger sample size and a more extended postoperative observation period would be required to assess the influence of

different surgical (tsAH or ATL) and possibly anti-inflammatory approaches in treating mTLE due to GO.

## CONCLUSION

This study provides confirmatory evidence that GO is distinct from HS based on histopathology, imaging and cognitive function. The two pathologies are associated with different seizure freedom rates after surgery and the risk of postoperative memory decline. The different risk–benefit ratio regarding the surgical treatment of GO calls for a more pathology-dependent surgical decision making and patient counselling.

Our results show that we need a better understanding of the pathomechanisms involved in GO, both regarding aetiology in the disease course and as the basis for more targeted and tailored treatments.<sup>31</sup>

**Contributors** JT, J-AW, CH, AG and DD generated the hypotheses and study design. All authors provided data and discussed the analysis plan. Results were discussed by all authors. All authors provided input to the manuscript. All authors were responsible for the critical revision of the article. All authors had access to the final study results and were responsible for the final approval of the manuscript. The corresponding author attested that all listed authors meet authorship criteria and that no others meeting the criteria have been omitted. JT accepts full responsibility for the work and/or the conduct of the study, had access to the data, and controlled the decision to publish.

**Funding** The authors have not declared a specific grant for this research from any funding agency in the public, commercial or not-for-profit sectors.

**Competing interests** CEE has served as a paid consultant for Desitin, Pfizer and UCB Pharma, outside of the submitted work; CH reports personal fees from Precisis, Eisai, UCB and GW, outside the submitted work; J-AW reports personal fees from Eisai, outside the submitted work; JT reports grants from EpiCARE & Arbeitsgemeinschaft für Prächirurgische Epilepsiediagnostik und operative Epilepsitherapie AG, outside the submitted work; DD, AG, AJB, EH and JE declare that they have no known competing financial interests or personal relationships that could have appeared to influence the work reported in this paper.

**Patient consent for publication** Not applicable.

**Ethics approval** This study involves human participants and was approved by all procedures performed in studies involving human participants were in accordance with the ethical standards of the institutional and/or national research committee and with the 1964 Declaration of Helsinki and its later amendments or comparable ethical standards. The study was reviewed and approved by the local ethics committee at the University of Bonn Medical Center (ID=360/12). Participants gave informed consent to participate in the study before taking part.

**Provenance and peer review** Not commissioned; externally peer reviewed.

**Data availability statement** No data are available.

## ORCID iD

Julia Taube <http://orcid.org/0000-0002-3593-8192>

## REFERENCES

- Blumcke I, Spreafico R, Haaker G, *et al.* Histopathological findings in brain tissue obtained during epilepsy surgery. *N Engl J Med* 2017;377:1648–56.
- Blümcke I, Thom M, Aronica E, *et al.* International consensus classification of hippocampal sclerosis in temporal lobe epilepsy: a task force report from the ILAE Commission on diagnostic methods. *Epilepsia* 2013;54:1315–29.
- Hattingen E, Enkirch SJ, Jurcoane A, *et al.* Hippocampal "gliosis only" on MR imaging represents a distinct entity in epilepsy patients. *Neuroradiology* 2018;60:161–8.
- Devinsky O, Vezzani A, Najjar S, *et al.* Glia and epilepsy: excitability and inflammation. *Trends Neurosci* 2013;36:174–84.
- Gillmann C, Coras R, Rössler K, *et al.* Ultra-high field MRI of human hippocampi: morphological and multiparametric differentiation of hippocampal sclerosis subtypes. *PLoS One* 2018;13:e0196008.
- Pimentel-Silva LR, Casseb RF, Cordeiro MM, *et al.* Interactions between in vivo neuronal-glia markers, side of hippocampal sclerosis, and pharmacoresponse in temporal lobe epilepsy. *Epilepsia* 2020;61:1008–18.
- Hansen N, Ernst L, Rüber T, *et al.* Pre- and long-term postoperative courses of hippocampus-associated memory impairment in epilepsy patients with antibody-associated limbic encephalitis and selective amygdalohippocampectomy. *Epilepsy Behav* 2018;79:93–9.
- Lamberink HJ, Otte WM, Blümcke I, *et al.* Seizure outcome and use of antiepileptic drugs after epilepsy surgery according to histopathological diagnosis: a retrospective multicentre cohort study. *Lancet Neurol* 2020;19:748–57.






- 9 Witt J-A, Coras R, Schramm J, et al. Relevance of hippocampal integrity for memory outcome after surgical treatment of mesial temporal lobe epilepsy. *J Neurol* 2015;262:2214–24.
- 10 Witt J-A, Coras R, Becker AJ, et al. When does conscious memory become dependent on the hippocampus? the role of memory load and the differential relevance of left hippocampal integrity for short- and long-term aspects of verbal memory performance. *Brain Struct Funct* 2019;224:1599–607.
- 11 Witt J-A, Coras R, Schramm J, et al. The overall pathological status of the left hippocampus determines preoperative verbal memory performance in left mesial temporal lobe epilepsy. *Hippocampus* 2014;24:446–54.
- 12 Helmstaedter C, Pohl C, Hufnagel A, et al. Visual learning deficits in nonresected patients with right temporal lobe epilepsy. *Cortex* 1991;27:547–55.
- 13 Ono SE, de Carvalho Neto A, Joaquim MJM, et al. Mesial temporal lobe epilepsy: revisiting the relation of hippocampal volumetry with memory deficits. *Epilepsy Behav* 2019;100:106516.
- 14 Sherman EMS, Wiebe S, Fay-McClymont TB, et al. Neuropsychological outcomes after epilepsy surgery: systematic review and pooled estimates. *Epilepsia* 2011;52:857–69.
- 15 Helmstaedter C, Petzold I, Bien CG. The cognitive consequence of resecting nonlesional tissues in epilepsy surgery—results from MRI- and histopathology-negative patients with temporal lobe epilepsy. *Epilepsia* 2011;52:1402–8.
- 16 Dulay MF, Busch RM. Prediction of neuropsychological outcome after resection of temporal and extratemporal seizure foci. *Neurosurg Focus* 2012;32:E4.
- 17 Helmstaedter CA. Prediction of memory reserve capacity. *Adv Neurol* 1999;81:271–9.
- 18 Witt JA, Helmstaedter C. Neuropsychologie bei Epilepsie Teil II: Gibt es eine gemeinsame Basis zur Etablierung diagnostischer Leitlinien? *Fortschritte der Neurologie Psychiatrie* 2009;77:691–8.
- 19 Helmstaedter C, Lendt M, Lux S. Verbaler Lern- und Merkfähigkeitstest: VLMT ; Manual. Beltz-Test, 2001. Available: <https://books.google.de/books?id=wETJsgAACAAJ>
- 20 Lux S, Helmstaedter C, Elger CE. Normative Study on the "Verbaler Lern- und Merkfähigkeitstest" (VLMT). *Diagnostica* 1999;45:205–11.
- 21 Gleissner U, Helmstaedter C, Schramm J, et al. Memory outcome after selective amygdalohippocampectomy in patients with temporal lobe epilepsy: one-year follow-up. *Epilepsia* 2004;45:960–2.
- 22 Helmstaedter C, Elger CE. Cognitive consequences of two-thirds anterior temporal lobectomy on verbal memory in 144 patients: a three-month follow-up study. *Epilepsia* 1996;37:171–80.
- 23 Helmstaedter C, Grunwald T, Lehnertz K, et al. Differential involvement of left temporolateral and temporomesial structures in verbal declarative learning and memory: evidence from temporal lobe epilepsy. *Brain Cogn* 1997;35:110–31.
- 24 Lamberti G, Weidlich S. *Dcs: a visual learning and memory test for neuropsychological assessment, after f. Hillers*. 3rd ed. Göttingen: Hogrefe & Huber Publishers, 1998.
- 25 Helmstaedter C, Richter S, Röske S, et al. Differential effects of temporal pole resection with amygdalohippocampectomy versus selective amygdalohippocampectomy on material-specific memory in patients with mesial temporal lobe epilepsy. *Epilepsia* 2008;49:88–97.
- 26 Zentner J, Wolf HK, Helmstaedter C, et al. Clinical relevance of amygdala sclerosis in temporal lobe epilepsy. *J Neurosurg* 1999;91:59–67.
- 27 Gleissner U, Helmstaedter C, Elger CE. Right hippocampal contribution to visual memory: a presurgical and postsurgical study in patients with temporal lobe epilepsy. *J Neurol Neurosurg Psychiatry* 1998;65:665–9.
- 28 Lehl S. *Mehrfachwahl-Wortschatz-Test (MWT-B)*, 1977.
- 29 Patrikelis P, Lucci G, Alexoudi A. The cognitive reserve model and its relation to preoperative neuropsychological rehabilitation in patients with refractory medial temporal lobe epilepsy: a perspective review 2018.
- 30 Dossi E, Vasile F, Rouach N. Human astrocytes in the diseased brain. *Brain Res Bull* 2018;136:139–56.
- 31 Bell ML, Rao S, So EL, et al. Epilepsy surgery outcomes in temporal lobe epilepsy with a normal MRI. *Epilepsia* 2009;50:2053–60.
- 32 Helmstaedter C. Cognitive outcomes of different surgical approaches in temporal lobe epilepsy. *Epileptic Disord* 2013;15:221–39.
- 33 Baxendale S, Thompson P. Red flags in epilepsy surgery: identifying the patients who pay a high cognitive price for an unsuccessful surgical outcome. *Epilepsy Behav* 2018;78:269–72.
- 34 Helmstaedter C. Neuropsychological complaints, deficits, and difficulties in everyday life. In: Pfäfflin M, Fraser RT, Thorbecke R, eds. *Comprehensive care for people with epilepsy*. London: John Libbey & Company Ltd, 2001: 293–306.
- 35 Helmstaedter C, Hauff M, Elger CE. Ecological validity of list-learning tests and self-reported memory in healthy individuals and those with temporal lobe epilepsy. *J Clin Exp Neuropsychol* 1998;20:365–75.
- 36 Rác A, Hummel CA, Becker A, et al. Histopathologic characterization and neurodegenerative markers in patients with limbic encephalitis undergoing epilepsy surgery. *Front Neurol* 2022;13:617.
- 37 Witt J-A, Meschede C, Helmstaedter C. Hazardous employment of invalid measures for cognitive outcome assessment: you only see what your test can show you. *Epilepsy Behav* 2021;117:107865.

### 3.4 Publication 4: Resection of piriform cortex predicts seizure freedom in temporal lobe epilepsy

## RESEARCH ARTICLE

# Resection of piriform cortex predicts seizure freedom in temporal lobe epilepsy

Valeri Borger<sup>1,a</sup> , Matthias Schneider<sup>1,a</sup>, Julia Taube<sup>2</sup>, Anna-Laura Potthoff<sup>1</sup>, Vera C. Keil<sup>3</sup>, Motaz Hamed<sup>1</sup>, Gülsah Aydin<sup>1</sup>, Inja Ilic<sup>1</sup>, László Solymosi<sup>3</sup> , Christian E. Elger<sup>2</sup>, Erdem Güresir<sup>1</sup> , Rolf Fimmers<sup>4</sup>, Patrick Schuss<sup>1</sup>, Christoph Helmstaedter<sup>2</sup>, Rainer Surges<sup>2</sup> & Hartmut Vatter<sup>1</sup>

<sup>1</sup>Department of Neurosurgery, University Hospital Bonn, Bonn, Germany

<sup>2</sup>Department of Epileptology, University Hospital Bonn, Bonn, Germany

<sup>3</sup>Department of Neuroradiology, University Hospital Bonn, Bonn, Germany

<sup>4</sup>Institute of Medical Biometry, Informatics and Epidemiology, University Hospital Bonn, Bonn, Germany

## Correspondence

Valeri Borger, Department of Neurosurgery, University Hospital Bonn, Venusberg-Campus 1, 53127 Bonn, Germany. Telephone: 0049 228 287 16500; Fax: 0049 228 287 14758; E-mail: valeri.borger@ukbonn.de

## Funding Information

No funding information provided.

Received: 28 August 2020; Revised: 7 November 2020; Accepted: 10 November 2020

*Annals of Clinical and Translational Neurology* 2021; 8(1): 177–189

doi: 10.1002/acn3.51263

<sup>a</sup>These authors contributed equally to the manuscript.

## Abstract

**Objective:** Transsylvian selective amygdalo-hippocampectomy (tsSAHE) represents a generally recognized surgical procedure for drug-resistant mesial temporal lobe epilepsy (mTLE). Although postoperative seizure freedom can be achieved in about 70% of tsSAHE, there is a considerable amount of patients with persisting postoperative seizures. This might partly be explained by differing extents of resection of various tsSAHE target volumes. In this study we analyzed the resected proportions of hippocampus, amygdala as well as piriform cortex in regard of postoperative seizure outcome. **Methods:** Between 2012 and 2017, 82 of 103 patients with mTLE who underwent tsSAHE at the authors' institution were included in the analysis. Resected proportions of hippocampus, amygdala and temporal piriform cortex as target structures of tsSAHE were volumetrically assessed and stratified according to favorable (International League Against Epilepsy (ILAE) class 1) and unfavorable (ILAE class 2–6) seizure outcome. **Results:** Patients with favorable seizure outcome revealed a significantly larger proportion of resected temporal piriform cortex volumes compared to patients with unfavorable seizure outcome (median resected proportional volumes were 51% (IQR 42–61) versus (vs.) 13 (IQR 11–18),  $P = 0.0001$ ). Resected proportions of hippocampus and amygdala did not significantly differ for these groups (hippocampus: 81% (IQR 73–88) vs. 80% (IQR 74–92) ( $P = 0.7$ ); amygdala: 100% (IQR 100–100) vs. 100% (IQR 100–100) ( $P = 0.7$ )). **Interpretation:** These results strongly suggest temporal piriform cortex to constitute a key target resection volume to achieve seizure freedom following tsSAHE.

## Introduction

Temporal lobe epilepsy (TLE) is one of the most common entities of epilepsy, first described by Hughlings-Jackson in 1898.<sup>1</sup> In approximately 30% of patients, seizures are refractory to drug treatment.<sup>2,3</sup> Since the first randomized controlled trial by Wiebe et al. has shown significantly improved outcomes with epilepsy surgery over drug treatment in refractory TLE, resective temporal lobe surgery (rTLS) has become a reasonable option for treatment in these patients.<sup>4</sup> Especially for the treatment

of mesial TLE (mTLE), a selective amygdalo-hippocampectomy via the transsylvian approach (tsSAHE) was introduced.<sup>5</sup> The aim of this approach was to perform a lesionectomy of mesiotemporal structures avoiding trauma to the adjacent healthy temporal neopallial areas and to the vasculature.<sup>6</sup> Despite reported seizure freedom rates between 60% and 70%, there is a considerable amount of patients with continued seizures after epilepsy surgery.<sup>7</sup> The reasons behind failure of surgery for mTLE are diverse and vary between cases. In the previous decades, many efforts were made to identify a sufficient

resection extent of mesiotemporal structures.<sup>8–12</sup> However, results from these studies have been conflicting and the issue of optimal extent of resection remains controversial.<sup>13</sup>

A recently published study by Galovic et al. reported strong evidence for the association of piriform cortex resection with surgical seizure outcome in patients with TLE who underwent a standard anterior temporal lobe (ATL) resection.<sup>14</sup> Thus, extended removal of the piriform cortex has been shown to significantly increase the probability of becoming seizure free. Against this backdrop, the piriform cortex seems to constitute a novel key target volume for ATL resections. However, the impact of piriform cortex resection in the setting of transylvian SAHE for treatment of mTLE is still unknown. Therefore, the aim of this study was to investigate whether the extent of piriform cortex resection might significantly contribute to postoperative seizure outcome in the course of tsSAHE.

## Methods

### Patient population and presurgical evaluation

Patients with TLE who underwent rTLS between 2012 and 2017 were reviewed from the prospectively kept epilepsy surgery database at our hospital. The establishment of this database was approved by the local ethics committee. Informed consent was not sought as a retrospective design was used.

During the studied period, rTLS was performed in a total of 184 patients. For patients suffering from unilateral mTLE, in our center the tsSAHE is the first-line surgical treatment option. The rationale for surgical procedure selection was based on the magnetic resonance imaging (MRI)-documented pathological lesion as well as putative epileptogenic tissue volumes as suggested in the course of preoperative clinical and electroencephalographical evaluation as previously described for our interdisciplinary epilepsy center.<sup>15</sup>

All patients were presurgically assessed in the department of epileptology and were considered to be suitable for surgery.<sup>16–18</sup> The evaluation included detailed history of seizures, medical history, high resolution structural 3.0 Tesla MRI, neuropsychological assessment,<sup>19</sup> and video-electroencephalography (EEG) monitoring using continuous recordings. In patients with absent or several lesions on MRI – the latter defined as any coexistent extratemporal lesion beyond the ipsilateral temporal lobe that had undergone surgery for tsSAHE – positron emission tomography (PET) and single-photon emission computed tomography (SPECT) were performed in order to

identify a seizure focus. In cases with nonconclusive findings, invasive EEG monitoring was performed using stereotactically implanted depth electrodes.<sup>20</sup> Following completed evaluation, the extent of resection was determined in every individual candidate by the interdisciplinary epilepsy conference.

Accordingly, the tsSAHE was performed in 103 consecutive patients. To establish a uniform code of study quality, we only included patients with (a) at least completed 12 months of follow-up after surgery; (b) available pre- and postsurgical structural magnetic resonance imaging (MRI) scans acquired according to the identical scanning protocol and (c) tsSAHE that was performed as a highly standardized surgical procedure by three neurosurgeons (H.V., V.B., M.H.). Considering the abovementioned inclusion criteria, 12 patients were lost to follow-up and nine patients had limited postoperative MRI-protocols. A total of 82 eligible patients were included in the analysis. All patients suffered from medically refractory mTLE and had undergone adequate treatment with at least two first-line antiepileptic drugs (AED).

### Surgical procedure of transylvian selective amygdalo-hippocampectomy

All surgical procedures were performed under general anesthesia using intraoperative neuronavigation and intraoperative neurophysiological monitoring with motor evoked potentials (MEP) and somatosensory evoked potentials (SSEP). The goal of surgery was to anatomically remove mesiotemporal target structures that entail presumed seizure focus. For SAHE, exclusively the transylvian approach as described by Yasargil et al.<sup>6</sup> with several modifications was used by all neurosurgeons. The surgery was performed as a highly standardized procedure. Shortly described, the patient is positioned supine, the head is fixed in Mayfield-Clamp turned 45° to the opposite side, and the vertex is tilted 5–10° to the bottom. A standard pterional craniotomy was performed. Attention was paid to extend the frontal margin of the bone flap to the mediopupillar line. After opening of the dura, the proximal sylvian fissure was dissected and the sylvian fossa was exposed. In the next step, the deep sylvian vein and limen insulae were identified and a small pial incision into the piriform cortex, 2–3 mm lateral to the M<sub>1</sub> segment and lateral to the deep sylvian vein, was performed. The resection of the superior and lateral parts of the amygdala was performed using neuronavigation and ultrasound suction system (CUSA) just along the lateral border and ventral to the tip of the temporal horn until the temporobasis was reached. From this point, the further resection of amygdala and uncus was performed using CUSA or Penfield dissector, until the pial and



arachnoid membranes, adjacent to the crural and ambient cisterns, was reached. The temporal horn was then opened using a dissector and the coroidal point was identified followed by resection of the anterior part of the hippocampus. The body of the hippocampus was then resected en bloc and obtained for histopathological analysis. The resection of dorsal parts of the hippocampus was extended until the level of the tectum.

### Imaging and volumetric analysis

All MRI studies were performed pre- and postoperatively at the same 3.0 Tesla scanner (Achieva TX, Philips Healthcare, Best, the Netherlands) with identical scanning protocols. All patients underwent MRI within 2–3 days postoperatively in order to detect the extent of resection of desired structures. The pre- and postoperative scans were measured as a pair by two independent and blinded raters. For postoperative assessment the same landmarks were used and preoperative outlines were transposed onto postoperative scans. The volumetric analysis was performed by A.-L.P. and M.S. after training and under continuous supervision provided by V.C.K. and L.S. (8 and 25 years of experience in tumor volumetry) using commercially available software (Intellispace 8.0, Philips Healthcare, Best, the Netherlands). V.C.K. checked and analyzed data for accuracy and methodological consistency afterwards. The volumes of amygdala, hippocampus and piriform cortex were obtained from presurgical and postsurgical 1mm isovoxel 3D T1-weighted MPRAGE scans. The resected proportions of amygdala, hippocampus and piriform cortex were then calculated in each individual. In this series, the segmentation and volumetry of hippocampus, amygdala and piriform cortex were manually performed by trained raters under continuous supervision by experienced neuroradiologists. Each hippocampus was traced in coronal, axial and sagittal plane. The entire length of each hippocampus was manually outlined to anatomic landmarks. The anterior border of the hippocampus was defined by distinguishing from amygdala by the presence of the alveus or the cerebrospinal fluid (CSF) of the lateral ventricle (e.g. uncal recess).<sup>21,22</sup> The posterior border was reached when the fornices were visible in their full length in sagittal plane. The anterior mesial border was defined by the posterior portions of the uncal fissure whereas the posterior mesial border was made up by the open end of the hippocampal fissure. The CSF of the lateral ventricle defines the lateral boundary of the hippocampus. The white matter of the parahippocampal gyrus below the subiculum defines the inferior limit. The manual volumetric segmentation of the amygdala was performed according to existing protocols.<sup>23</sup> In short, the posterior border was defined in the

coronal plane by the alveus that appears inferiorly to the amygdala and the head of the hippocampus, which is inferior-medial. The axial plane was used to identify the medial and lateral border. The ambient cistern limited the medial boundary. The lateral border was defined by the inferior horn of the lateral ventricle. For the identification of the inferior border, the amygdala was traced in the coronal slices. The tentorial indentation was a demarcation line between amygdala and entorhinal cortex. The anterior limit was defined at the level of the closure of lateral sulcus, which could easily be found in the axial sections.

For volumetric analysis of piriform cortex, we basically employed the work reported by Vaughan and Jackson. Thus, the human piriform cortex was subdivided in a frontal and a temporal part. In the temporal lobe, the piriform cortex becomes contiguous to periamygdaloid cortex both anatomically and functionally, and posteriorly extends to overlie the amygdala complex. Medially, piriform cortex limits to the entorhinal cortex with the sulcus semiannularis as its border. In the frontal lobe, the piriform cortex extends from the fundus of the entorhinal sulcus, and is limited medially by the olfactory tubercle and the lateral olfactory tract. The extent of the piriform cortex in the posterior – anterior direction in coronal plane begins at the level of the opening of the hippocampal fissure. From this level, the anterior limit is at the level of the limen insulae. The frontal part of the piriform cortex was defined in accordance to Vaughan and Jackson<sup>24</sup> as a triangular region, which starts from the fundus of the entorhinal sulcus and is bounded medially by the olfactory tubercle and the lateral olfactory tract. The boundary between the superior medial border of the amygdala and piriform cortex is represented by the periamygdaloid cortex (PAC) area. Given by the fact, that in the MR imaging, the discrimination between PAC and piriform cortex is not possible, we grouped the piriform cortex and PAC together for further volumetric analysis. This approach is feasible because both these areas are closely connected both spatially and functionally and were also previously reported by Gonçalves Pereira *et al.*<sup>25</sup>

Due to its eloquent localization and inherent risk of vascular damage, the frontal part of the piriform cortex was not intended for resection during tsSAHE. Given by this fact, we consequently excluded the frontal part of the piriform cortex for volumetric analysis.

### Seizure outcome analysis

Seizure outcome was assessed during follow-up visits at 6 and 12 months. At the 12 months visit, all patients underwent thorough clinical examination, evaluation of seizure outcome, Video-EEG recording, high resolution

structural 3 Tesla MRI, and neuropsychological reassessment. Postoperative seizure outcome was assessed according to the ILAE classification.<sup>26</sup> Patients were divided into two groups according to the seizure outcome (group I: ILAE class 1; group II: ILAE class  $\geq 2$ ). The ILAE class 1 outcome was considered favorable, the ILAE class  $\geq 2$  outcome unfavorable.

### Statistical analysis

Statistical data analysis was performed using software package SPSS (IBM SPSS Statistics for Windows, Version 25.0. Armonk, NY: IBM Corp.). Associations between parametric variables were analyzed using unpaired, two-tailed Student *t*-test. The Mann-Whitney-*U* test was chosen to compare continuous variables as the data were largely not normally distributed. Associations of categorical variables were compared using Chi-square test or Fisher exact test. Results with  $P < 0.05$  were considered to be statistically significant. For identification of independent risk factors for unfavorable postoperative seizure outcome (ILAE class  $\geq 2$ ), a two-level logistic regression analysis was performed including the variables with significant *P*-values in univariate analysis. The results of the analysis were presented as odds ratios (OR) with 95% confidential interval (CI). Finally, receiver operating characteristic (ROC) analysis was performed to explore the power of the resulting model.

### Neuropsychological assessment

The neuropsychological evaluation focused on tests of verbal and nonverbal memory representing temporal lobe functions. In addition, attention and executive functions, visuo-spatial abilities, language and motor functions were considered. Verbal learning and memory were measured via the VLMT, a German adaptation of the Rey Auditory Verbal Learning Test.<sup>27</sup> For nonverbal learning and memory the revised version of the DCS-R was applied.<sup>28</sup> Parallel versions of the VLMT and DCS-R were employed to minimize practice effects at the follow-up. Attention was assessed by the EpiTrack<sup>29</sup> and a letter cancellation task. Language assessment comprised confrontation naming and a comprehension task (Token Test). Evaluation of visuo-spatial abilities was carried out by administering mental rotation and WAIS block design. The tests and their references are described in previous articles.<sup>30</sup>

Pre- and postoperative test results from each cognitive domain were summarized and classified into a five-point scale ranging from severely impaired to above average (severely impaired = 0, at least two test scores  $> 2SD$  below the mean of the normative sample; impaired = 1, at least two test scores  $> 1SD$  below the mean; borderline = 2, one test score below the mean; unimpaired = 3,

no test score  $> 1SD$  below the mean; above average = 4, at least two test scores  $> 1SD$  above the mean). The distance between two subsequent categories approximately corresponds to one SD from the mean standardized score across all test scores of the respective domain.<sup>31</sup>

### Statistical analysis

The neuropsychological outcome was defined as the intraindividual change of cognitive categories from pre- to postoperative assessment. Therefore, we subtracted the postoperative from the preoperative category score per domain. A positive value indicated improvement, a negative value indicated deterioration, a value of zero indicated no change.<sup>30</sup> To investigate postoperative changes depending on the side of surgery we performed chi-square tests for each cognitive domain (attention, verbal memory, visual memory, language). In addition, language was examined with separate repeated measures analyses of variance with raw scores from the Token Test, Boston Naming Test and phonemic fluency as within-subjects factors and side of surgery as the between-subjects factor. We chose nonparametric tests, since our data were not normally distributed. To predict which factors influence the postoperative cognitive outcome, separate multiple linear regressions (enter method) were calculated for each cognitive domain. As potential predictors we included the extent of resection of piriform cortex, baseline performance, seizure freedom, and side of surgery as independent variables.

## Results

### Patient characteristics

Between 2012 and 2017, 82 patients with drug-resistant mTLE underwent tsSAHE at the authors' institution. Postoperative seizure freedom in terms of ILAE class 1 could be achieved for 59 patients (72%) (Table 1).

Side of surgery did not significantly impact the postoperative seizure outcome: 30/42 patients (71%) were seizure free after left tsSAHE and 29/40 patients (73%) were seizure free after right tsSAHE ( $P = 1.0$ ).

In the course of pre-surgical evaluation, invasive diagnostics using depth electrodes were performed in 12 patients (20%) within the ILAE class 1 group and nine patients (39%) within the ILAE class 2–6 group ( $P = 0.1$ ). The histopathological analysis revealed that 52 out of 67 (88%) patients with hippocampal sclerosis had a favorable outcome, compared to seven out of 15 (47%) patients with gliosis or other pathology. Piriform cortices did not exhibit any identifiable preoperative MRI lesions. Coexistent MRI lesions comprised extratemporal gliosis in 9/59 patients (15%) and gray-white differentiation disorders in 5/59

**Table 1.** Baseline patient characteristics according to ILAE class seizure outcome<sup>1</sup>.

Characteristics	ILAE class 1 (n = 59)	ILAE class 2 -6 (n = 23)	P Value
Sex			
Male, n (%)	28 (47)	14 (61)	0.33
Female, n (%)	31 (53)	9 (39)	
Age at epilepsy onset (mean years ± SD)	16.8 ± 14.2	17.0 ± 12.1	
Duration of epilepsy (mean years ± SD)	22.7 ± 13.2	20.0 ± 16.4	
Age at surgery (mean years ± SD)	39.2 ± 14.1	36.2 ± 14.2	
Site of surgery			
Left, n (%)	30 (51)	12 (52)	1.0
Right, n (%)	29 (49)	11 (48)	
Invasive presurgical evaluation with depth electrodes n (%)	12 (20.3)	9 (39)	0.1
Preoperative MRI findings			
Unilateral hippocampal sclerosis, n (%)	52 (88.1)	16 (69.6)	0.06
No lesion, n (%)	4 (6.8)	5 (21.7)	0.11
Hippocampal gliosis, n (%)	1 (1.7)	2 (8.6)	0.19
Unspecific hippocampal lesion	2 (3)	0 (0)	1.0
Coexistent lesions <sup>2</sup>	10 (17)	4 (21)	1.0
Histology of hippocampus			
Hippocampal sclerosis, n (%)	52 (88.1)	15 (65.2)	0.03
Hippocampal gliosis, n (%)	7 (11.9)	6 (26.1)	0.18
Others, n (%)	0 (0.0)	2 (8.7)	0.08
Peri- and postoperative complications	2 (3)	3 (13)	0.1

ILAE, International League Against Epilepsy; SD, standard deviation.

<sup>1</sup>Values represent number of patients unless otherwise indicated (%).

<sup>2</sup>Defined as any coexistent extratemporal lesion beyond the ipsilateral temporal lobe of surgery.

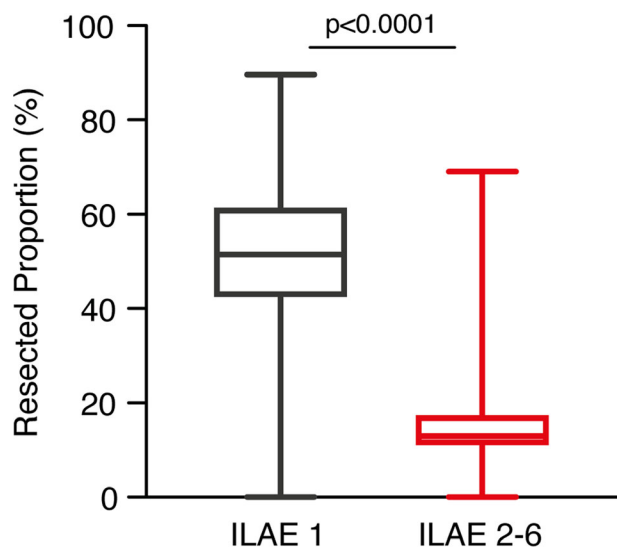
patients (8%). Peri- and postoperative complications were present in five out of 82 patients (6%) and accounted for postoperative bleeding in one case (1%) and postoperative wound infection and meningitis in four cases (5%). Further, peri- and postoperative unfavorable events did not significantly impact the postoperative seizure outcome: two out of 59 (3%) patients with ILAE class 1 and three out of 23 (13%) patients with ILAE class 2–6 ( $P = 0.1$ ) exhibited surgery-associated complications. For further details on patient characteristics see Table 1.

### Extent of temporal piriform cortex resection predicts postoperative seizure outcome

While volumetric analysis of pre- and postoperative target volumes did not yield significant differences in the resected proportions of hippocampus and amygdala for

the ILAE class 1 and ILAE class 2–6 groups (hippocampus: 81% (IQR 73–88) for favorable versus (vs.) 80% (74–92) for unfavorable seizure outcome ( $P = 0.7$ ); amygdala: 100% (100–100) vs. 100% (100–100) ( $P = 0.6$ )), patients with postoperative seizure freedom revealed a profound reduction in residual piriform cortex volumes. Thereby, patients with favorable seizure outcome exhibited a median resected proportion of 51% (42–61) compared to 13% (11–18) for patients with postoperative persisting or deteriorating seizures ( $P = 0.0001$ ) (Fig. 1, Table 2).

Figure 2 illustrates the anatomical topography of hippocampus, amygdala and piriform cortex as target volumes in tsSAHE surgery. Examples of differing extents of piriform cortex resection are given in Figure 3. Preoperative volumes of abovementioned tsSAHE target structures did not significantly differ between the groups of favorable and unfavorable seizure outcome (Table 3). The volumetric analysis of tsSAHE target volumes according to affected side by the mTLE is shown in Tables S1 and S2. Additionally, we analyzed the impact of the extent of piriform cortex resection in patients with histological evidence of hippocampal sclerosis and in those without this pathology. Thereby, we did not find any significant correlation (Table 4). In order to check for a potential influence of hippocampal sclerosis and the extent of piriform cortex resection as variables both of which were significantly associated with postoperative seizure outcome in univariate analysis, a two-level logistic regression analysis including an interaction term was performed. Thereby,



**Figure 1.** Box-Whisker Plots illustrate seizure outcome dependent on the proportion of temporal piriform cortex resection. ILAE, International League Against Epilepsy.

**Table 2.** Extent of temporal piriform cortex resection predicts postoperative seizure outcome.

	Resected proportion <sup>1</sup> (median (IQR))		
	ILAE class 1 (n = 59)	ILAE class 2–6 (n = 23)	P Value
Piriform cortex	51 (42–61)	13 (11–18)	0.0001
Hippocampus	81 (73–88)	80 (74–92)	0.7
Amygdala	100 (100–100)	100 (100–100)	0.6

ILAE, International League Against Epilepsy; IQR, interquartile range.

<sup>1</sup>Values indicated in %.

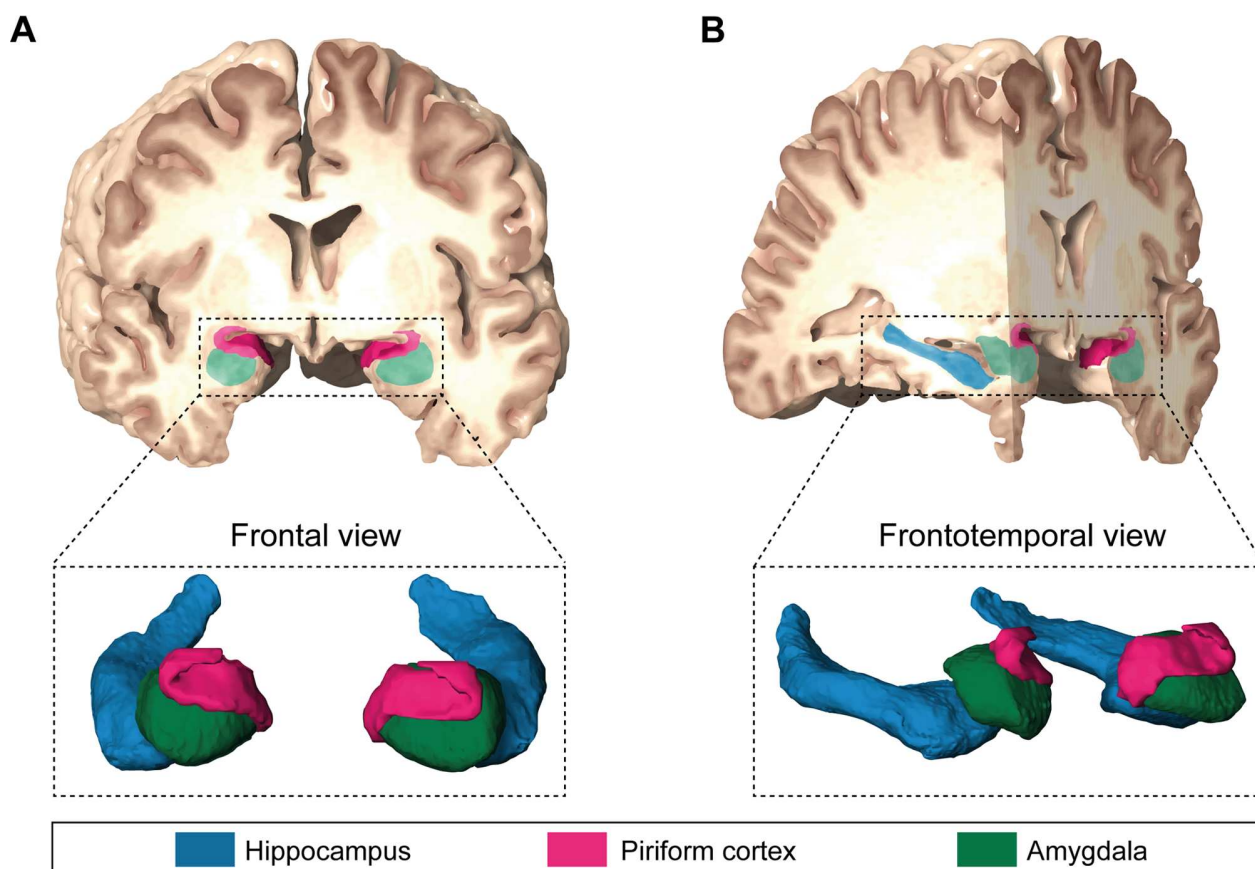
we could not find any evidence for potential interactions between these two variables ( $P = 0.09$ ).

The ROC analysis revealed that 50 out of 59 patients (85%) with postoperative seizure freedom (ILAE class 1) had undergone resection of more than 26.4% of preoperative temporal piriform cortex volumes. In comparison, 21 out of 23 patients (91%) with postoperative persistent or deteriorated seizures (ILAE class 2–6)

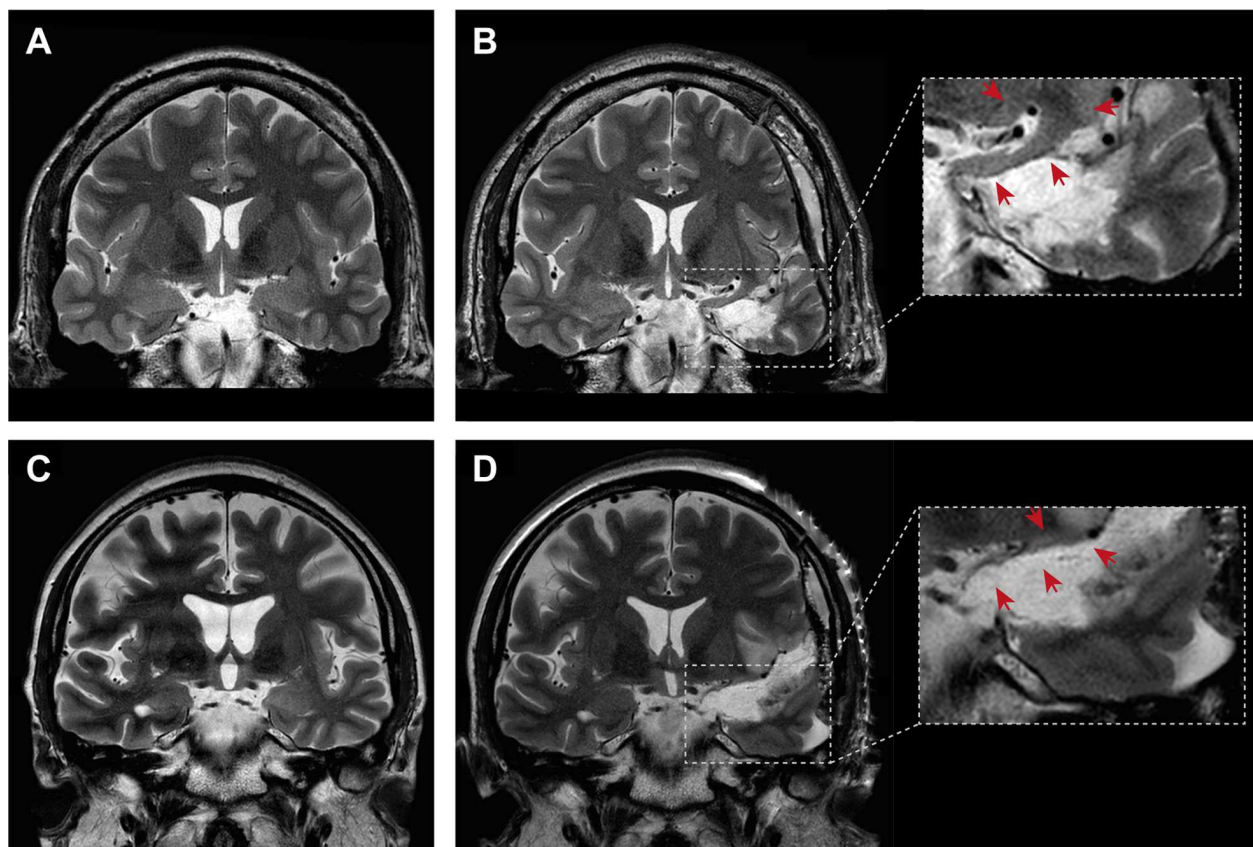
exhibited resection of less than 26.4% of preoperative temporal piriform cortex volumes (Fig. 4, Table 5). As shown in Table 6, the extent of piriform cortex resection did not correlate with the new onset of neurological deficits including new visual field impairment.

### Neurocognitive outcome

At baseline, cognitive impairments affected the majority of patients undergoing tsSAHE. Visual memory was most frequently impaired in 70% followed by verbal memory, language and attention in about 50% of the patients (Fig. 5). Postoperative assessments revealed that performance in verbal memory tasks dropped in 60% after left tsSAHE and in 27% after right tsSAHE ( $X^2(2) = 6.87$ ,  $P = 0.032$ ). Visual memory deteriorated in 33% after TLS regardless of side. In contrast, attention improved in 33%, language remained stable in 60% of the patients. Significant changes in language were found for phonemic fluency ( $F(1,39) = 7.43$ ,  $P < 0.05$ ,  $\eta^2 = 0.01$ ) and confrontation naming ( $F(1,55) = 9.55$ ,  $P < 0.05$ ,  $\eta^2 = 0.15$ ).



**Figure 2.** Illustration of anatomical topography of mesiotemporal target structures in tsSAHE. tsSAHE, transylvian selective amygdalo-hippampectomy.



**Figure 3.** Representative coronal T2-weighted MRI of tsSAHE with differing extent of piriform cortex resection. Pre-(A) and postoperative (B) images show profound residual volume of piriform cortex compared to a high extent of piriform cortex resection for respective images (C) and (D). Red arrows in the enlarged sections point at postoperative residual piriform cortices.

**Table 3.** Preoperative volumetric analysis of tsSAHE target structures according to seizure outcome.

	Volumes <sup>1</sup> (median (IQR))		
	ILAE class 1 (n = 59)	ILAE class 2–6 (n = 23)	P Value
Piriform cortex	0.39 (0.31–0.47)	0.40 (0.32–0.51)	0.7
Hippocampus	1.81 (1.54–2.36)	1.99 (1.71–2.50)	0.2
Amygdala	1.05 (0.88–1.24)	1.12 (0.93–1.41)	0.2

ILAE, International League Against Epilepsy; SD, standard deviation; tsSAHE, transylvian selective amygdalo-hippocampectomy.

<sup>1</sup>Values indicated in ml.

Confrontation naming improved after right tsSAHE and deteriorated after left tsSAHE. Phonemic fluency improved from pre- to postoperative assessment. The pre- and postoperative memory profile for patients with a smaller resection extent (less than median) and for patients with a larger resection extent (more than median) is displayed in Figure 6.

**Table 4.** Extent of piriform cortex resection dependent on postoperative histological analysis.

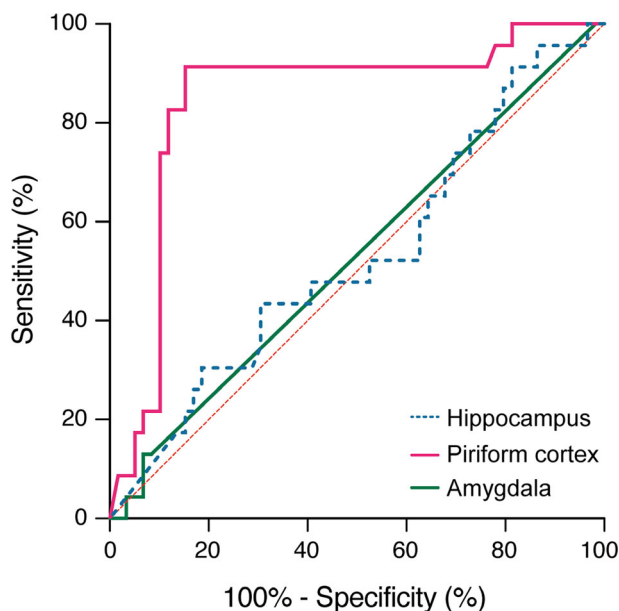
	Proportion of piriform cortex resection <sup>1</sup> (median (IQR))		
	ILAE class 1 (n = 59)	ILAE class 2–6 (n = 23)	P Value
Hippocampal sclerosis	50 (42–61)	13 (12–18)	0.0002
Hippocampal gliosis	62 (43–85)	13 (7–20)	0.0012

ILAE, International League Against Epilepsy; IQR, interquartile range; tsSAHE, transylvian selective amygdalo-hippocampectomy.

<sup>1</sup>Values indicated in %.

According to regression analyses, baseline performance, surgical side, seizure outcome and extent of piriform cortex resection have proven to be good predictors of postoperative cognitive outcome explaining between 29% (attention) and 56% (language) of the variance (Table 7). Baseline performance is the best predictor for attention,





**Figure 4.** Illustration of the association between piriform cortex, amygdala and hippocampus as target structures and seizure outcome in tsSAHE. Receiver operating characteristic curves (ROC) reveals the piriform cortex as the only target volume in tsSAHE to significantly discriminate between favorable and unfavorable seizure outcome. tsSAHE, transylvian selective amygdalo-hippocampectomy.

**Table 5.** Seizure outcome dependent on the proportion of temporal piriform cortex resection.

	Number of patients		
	ILAE class 1	ILAE class 2–6	Total
EOR < 26%	9	21	30
EOR ≥ 26%	50	2	52
Total	59	23	82

EOR, extent of resection; ILAE, International League Against Epilepsy.  $P < 0.0001$ .

**Table 6.** New postoperative neurological deficits dependent on the extent of piriform cortex resection<sup>1</sup>.

	EOR < 26% ( <i>n</i> = 30)	EOR ≥ 26% ( <i>n</i> = 52)	<i>P</i> Value
New transient motor deficit	0 (0)	1 (2) <sup>2</sup>	1.0
New transient aphasia	1 (3)	0 (0)	0.4
New visual deficit	17 (61)	33 (63)	0.6
quadrantanopsia	13 (43)	27 (52)	0.5
homonymous hemianopsia	4 (13)	6 (12)	1.0

EOR, extent of resection.

<sup>1</sup>Values represent number of patients unless otherwise indicated (%).

<sup>2</sup>transient hemiparesis.

memory and language. In addition, side of surgery also predicted the outcome of verbal memory. According to the  $\beta$  weights the extent of piriform cortex resection contributed little to the regression models.

## Discussion

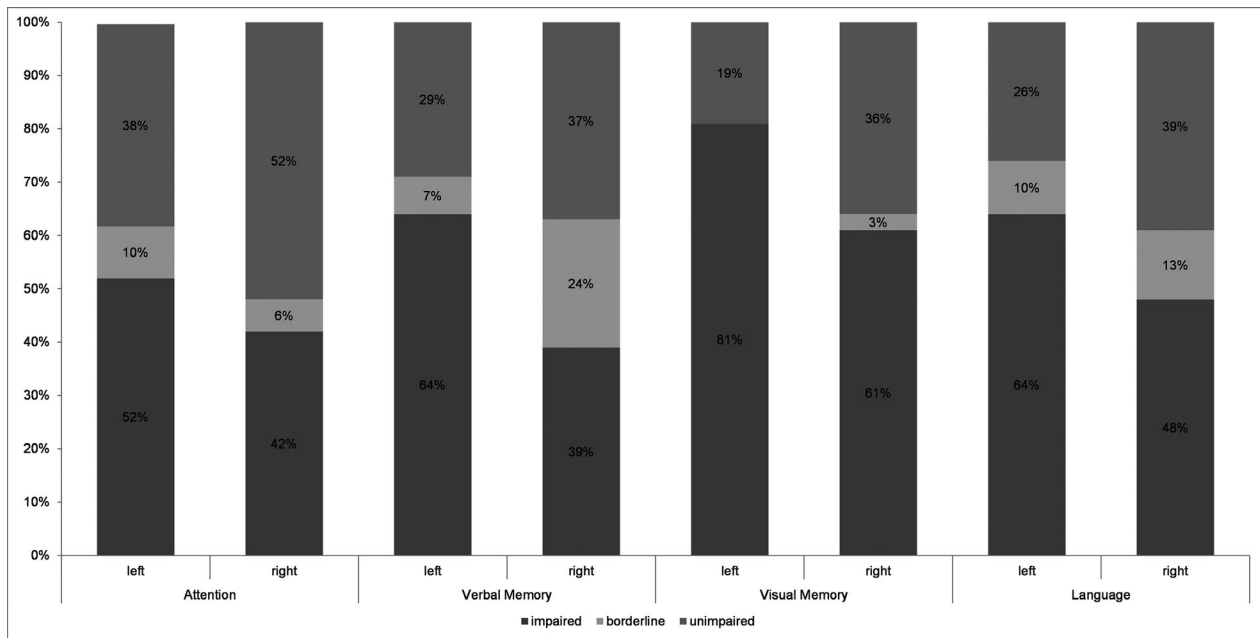
In this study, we presented results from one of the largest cohorts comparing preoperative and postoperative volumetric data on MRI exclusively in candidates suffering from mTLE and surgically treated using tsSAHE.<sup>32</sup> We showed that extended resection of piriform cortex profoundly predicts seizure freedom following tsSAHE in patients with mTLE.

In 1990 Siegel et al. provided the first study on 30 patients with TLE, who had undergone tsSAHE with the focus on the relationship between seizure outcome and volumetrically estimated amount of removal within temporomesial structures.<sup>33</sup> They found that smaller resection in the cranio-caudal axis was associated with a poorer seizure outcome. Furthermore, the authors concluded that incomplete resection of the parahippocampal gyrus and the subiculum results in less favorable seizure outcome.

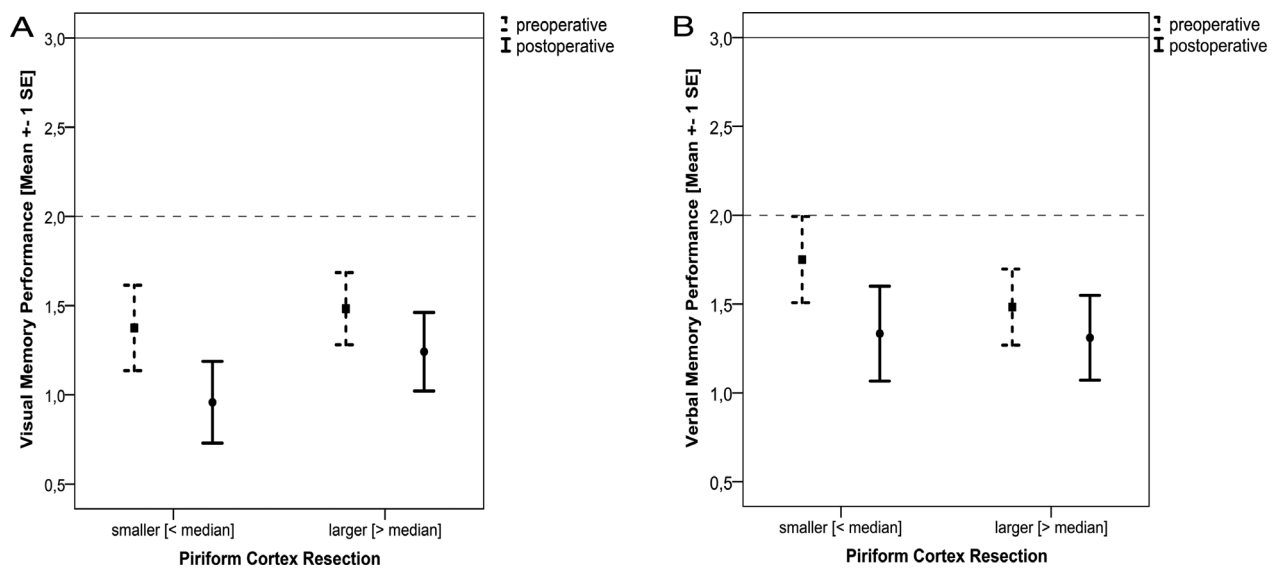
Recently published data by Galovic et al. comparing the association between volumetrically calculated extent of resection in the course of ATL and seizure outcome in individuals suffering from TLE<sup>14</sup> suggest that seizure freedom was achieved in 60% of patients if at least 50% of piriform cortex had been resected. In contrast to the findings by Siegel et al., the analysis performed by Galovic et al. revealed no significant difference in the amount of resection of entorhinal cortex between seizure free patients and patients with continued seizures after ATL. The results of our series are in line with the findings made by Galovic and coworkers. However, in contrast with these findings, in the current series a removal of at least 26.4% of the temporal part of piriform cortex was required to achieve seizure freedom in 96% of patients following tsSAHE.

In their study, Galovic and coworkers used outlining methods for manual segmentation largely based on the publication reported by Conçalves Pereira et al. The authors reported, that particularly in the frontal lobe, the outlining of borders of piriform cortex could be difficult. Therefore, to obtain more reliable estimates of piriform cortex volumes, they focused on the temporal extension of the piriform cortex. It is important to recognize, that in the study reported by Conçalves Pereira et al., the MR images were acquired on 1.5 T MR scanner with a slice thickness of 1.5–2.0 mm. In contrast, we performed entire pre- and postoperative MR scans on a 3.0 T MR scanner with a slice thickness of 1.0 mm. A similar scan protocol was applied in the study by Galovic et al. According to





**Figure 5.** Histogram demonstrates the results of the preoperative cognitive performance. The results from each cognitive domain summarized and classified into a five-point scale ranging from severely impaired to above average. The values represent cumulative percentage of performance categories in each tested cognitive domain according to the side of the TLE.



**Figure 6.** Performance in visual (A) and verbal memory (B) before and after surgery according to the extent of piriform cortex resection.

the work reported by Vaughan and Jackson, in our study we extended the outlining of the frontal part of the piriform cortex from the endorhinal sulcus to olfactorial tubercle limiting it by the lateral olfactorial tract. In contrast to our study, Galovic et al. included only 50–75% of this distance in the volumetric analysis. In light of this aspect, the segmentation and volumetry of the frontal

part of the piriform cortex was performed slightly more extensively in our study, compared to the method used by Galovic et al.

The outlining of the temporal part of piriform cortex was performed in the same fashion as reported by Galovic et al. Of note is that the frontal part of the piriform cortex was not included for volumetric analysis in the

**Table 7.** Results of regression analysis for prediction of postoperative neurocognitive outcome.

	$R^2_{adj.}$	$F$	$P$	Variable	$\beta$	$t$	$P$
Attention	0.29	7.07	<0.001	Baseline	0.50	4.39	<0.001
				Seizure freedom	0.11	0.29	0.77
				Surgical side	0.04	0.15	0.88
Verbal memory	0.34	9.16	<0.001	Piriform cortex	0.01	1.94	0.06
				Baseline	0.54	4.76	<0.001
				Surgical side	0.61	2.30	<0.05
				Seizure Freedom	-0.57	-1.49	0.14
Visual Memory	0.51	14.85	<0.001	Piriform cortex	-0.01	-1.55	0.13
				Baseline	0.73	7.57	<0.001
				Surgical side	-0.09	-0.43	0.67
				Seizure Freedom	0.01	0.02	0.98
Language	0.56	17.83	<0.001	Piriform cortex	0.00	0.86	0.39
				Baseline	0.60	7.10	<0.001
				Surgical side	0.33	1.96	0.06
				Seizure Freedom	-0.24	-1.04	0.30
				Piriform cortex	0.00	0.47	0.64

present series. This difference should be taken into account, when interpreting both these studies in regard of the required proportion of piriform cortex resection. However, the results of our study strongly support the evidence, that a more extensive resection of the temporal part of the piriform cortex is associated with a significantly higher chance to become seizure free after tsSAHE in mTLE.

Additionally, the abovementioned discrepancy in required amount of piriform cortex resection may be caused by the fact that the population in our series consists of candidates suffering from mTLE who represent a more homogeneous group of patients with a highly assumed seizure focus within the mesiotemporal structures. Therefore, extended resection of piriform cortex during tsSAHE in patients with mTLE might be more successful in removing the seizure foci compared to piriform cortex resection during ATL in patients with TLE.

Interestingly, a recent study of Wu et al. on laser interstitial thermal therapy (LITT) as a minimally invasive treatment for mesial temporal lobe epilepsy yielded superior seizure outcomes for ablation of more mesial and anterior located target structures than in the case of dorso-lateral tracts within the hippocampal body.<sup>34</sup> Notwithstanding reported data do not allow for distinct topographical analysis of piriform cortex volumes and therefore might partly explain worse overall seizure freedom rates compared to our series, these results may support the findings of strictly mesiotemporal located target volumes to significantly entail postoperative superior favorable seizure outcome rates.

In regard to neuropsychological outcome, the results in the current series are in line with previously reported

studies.<sup>19,35</sup> Resection of piriform cortex was safe and there was no impact on neurocognitive performance in regard of extent of resection. Although the role of piriform cortex in initiation and propagation of seizures is well described in animal models, there is little evidence regarding the exact function of piriform cortex in humans.<sup>36-38</sup> Therefore, further research is required to correlate the extent of resection with both seizure as well as neurocognitive outcome.

Of note is that the resection of piriform cortex using the transylvian approach for SAHE is more challenging for the surgeon due to several aspects. One of the main limitations is a narrow operative space and restricted visualization of the temporal part of the piriform cortex. There is often a need for additional dissection of the brain tissue or even retraction in order to attempt a better visualization of the operating field. These maneuvers may be risky as parts of basal ganglia, M<sub>1</sub> segment of the middle cerebral artery and other vessels traversing the anterior perforated substance could be affected. Despite this potential risk, our data strongly indicate that an effort to access and remove the temporal part of the piriform cortex should be made by the neurosurgeon during tsSAHE.

With regard to an extension of piriform cortex resection to significantly improve favorable seizure outcome, this study supports the hypothesis that the piriform cortex may profoundly be involved in the genesis of seizures in the temporal lobe. In addition to the evidence that the piriform cortex is a part of an epileptogenic network in rodent models,<sup>39-44</sup> there are several studies that provide evidence that piriform cortex might also be involved in the genesis and spreading of epileptic seizures in humans.<sup>24,45,46</sup> However, when analyzing the reasons

associated with failure of epilepsy surgery in mTLE, the role of piriform cortex and its extent of resection during the surgical procedure were underestimated in the literature.

One of the strengths of the present series is the homogeneous study population consisting of candidates with mTLE. Another strength is that the surgical procedure (tsSAHE) was performed in a highly standardized fashion in all patients. The imaging used for volumetric analysis was obtained from the same MRI scanner according to the standardized scanning protocol in all individuals. Despite the retrospective nature of data analysis, data acquisition was prospective. Patients were not randomized, but treated according to the decision of the interdisciplinary epilepsy surgery conference. Beyond doubt this study has several limitations. Due to its retrospective design, our study suffers from the risk of bias inherent to retrospective cohort analysis. Additionally, the present data represent a single-center experience. However, the implementation of a standardized neurosurgical approach and strict definition of inclusion criteria and variables analyzed in the current series might mitigate some of the shortcomings of a retrospective study design.

This study provides strong evidence for temporal piriform cortex as a novel key target structure in tsSAHE surgery. With regard to a profound increase in the rate of postoperative seizure freedom following extended piriform cortex resection, the authors suggest a renewed and enhanced surgery regime. The resection strategy during tsSAHE should take into account the residual temporal piriform cortex volume as a pivotal predictor for postoperative seizure outcome in mTLE.

## Acknowledgment

Open access funding enabled and organized by ProjektDEAL.

## Author Contributions

VB and MS conceived the study, statistical analysis, and interpretation of the data. VB and MS contributed equally to this work by designing and writing the draft of the manuscript. HV supervised the whole process of analysis and writing of the manuscript. All co-authors made substantial contribution to the conception of the study, the treatment and recruitment of the patients and data collection. EG and PS revised the manuscript critically. All co-authors approved the final version. RF supervised the statistical analysis and its interpretation. A-LP and MS performed volumetric analysis after training and under continuous supervision provided by VCK and LS. The neuropsychological assessment was performed and

analyzed by JT and CH. The collection of patient data was performed by GA and II. CEE and RS are responsible for the presurgical evaluation. The surgical procedures were performed by HV, VB and MH.

## Conflicts of Interest

The authors report no disclosures relevant to the manuscript.

## REFERENCES

1. Taylor DC, Marsh SM. Hughlings Jackson's Dr Z: the paradigm of temporal lobe epilepsy revealed. *J Neurosurg Psychiatr* 1980;43:758–767.
2. Choi H, Sell RL, Lenert L, et al. Epilepsy surgery for pharmacoresistant temporal lobe epilepsy: a decision analysis. *JAMA* 2008;300:2497–2505.
3. Engel J Jr. Surgical treatment for epilepsy: too little, too late? *JAMA* 2008;300:2548–2550.
4. Wiebe S, Blume WT, Girvin JP, et al. A randomized, controlled trial of surgery for temporal-lobe epilepsy. *N Engl J Med* 2001;345:311–318.
5. Wieser HG, Yasargil MG. Selective amygdalohippocampectomy as a surgical treatment of mesiobasal limbic epilepsy. *Surg Neurol* 1982;17:445–457.
6. Yasargil MG, Krayenbuhl N, Roth P, et al. The selective amygdalohippocampectomy for intractable temporal limbic seizures. *J Neurosurg* 2010;112:168–185.
7. de Tisi J, Bell GS, Peacock JL, et al. The long-term outcome of adult epilepsy surgery, patterns of seizure remission, and relapse: a cohort study. *Lancet* 2011;378:1388–1395.
8. Hennessy MJ, Elwes RD, Binnie CD, Polkey CE. Failed surgery for epilepsy. A study of persistence and recurrence of seizures following temporal resection. *Brain* 2000;123(Pt 12):2445–2466.
9. Wyler AR, Hermann BP, Richey ET. Results of reoperation for failed epilepsy surgery. *J Neurosurg* 1989;71:815–819.
10. Abosch A, Bernasconi N, Boling W, et al. Factors predictive of suboptimal seizure control following selective amygdalohippocampectomy. *J Neurosurg* 2002;97:1142–1151.
11. Schramm J, Lehmann TN, Zentner J, et al. Randomized controlled trial of 2.5-cm versus 3.5-cm mesial temporal resection in temporal lobe epilepsy—Part 1: intent-to-treat analysis. *Acta Neurochir (Wien)* 2011;153:209–219.
12. Schramm J, Lehmann TN, Zentner J, et al. Randomized controlled trial of 2.5-cm versus 3.5-cm mesial temporal resection—Part 2: volumetric resection extent and subgroup analyses. *Acta Neurochir (Wien)* 2011;153:221–228.
13. Harroud A, Bouthillier A, Weil AG, Nguyen DK. Temporal lobe epilepsy surgery failures: a review. *Epilepsy Res Treat* 2012;2012:201651.

14. Galovic M, Baudracco I, Wright-Goff E, et al. Association of piriform cortex resection with surgical outcomes in patients with temporal lobe epilepsy. *JAMA Neurol* 2019;76:690–700.
15. Grivas A, Schramm J, Kral T, et al. Surgical treatment for refractory temporal lobe epilepsy in the elderly: seizure outcome and neuropsychological sequels compared with a younger cohort. *Epilepsia* 2006;47:1364–1372.
16. Bien CG, Raabe AL, Schramm J, et al. Trends in presurgical evaluation and surgical treatment of epilepsy at one centre from 1988–2009. *J Neurol Neurosurg Psychiatry* 2013;84:54–61.
17. Kral T, Clusmann H, Urbach J, et al. Preoperative evaluation for epilepsy surgery (Bonn Algorithm). *Zentralbl Neurochir* 2002;63:106–110.
18. Ruber T, David B, Elger CE. MRI in epilepsy: clinical standard and evolution. *Curr Opin Neurol* 2018;31:223–231.
19. Helmstaedter C. Cognitive outcomes of different surgical approaches in temporal lobe epilepsy. *Epileptic Disord* 2013;15:221–239.
20. Wellmer J, von der Groeben F, Klarmann U, et al. Risks and benefits of invasive epilepsy surgery workup with implanted subdural and depth electrodes. *Epilepsia* 2012;53:1322–1332.
21. Konrad C, Ukas T, Nebel C, et al. Defining the human hippocampus in cerebral magnetic resonance images—an overview of current segmentation protocols. *NeuroImage* 2009;47:1185–1195.
22. Winston GP, Cardoso MJ, Williams EJ, et al. Automated hippocampal segmentation in patients with epilepsy: available free online. *Epilepsia* 2013;54:2166–2173.
23. Pruessner JC, Li LM, Serles W, et al. Volumetry of hippocampus and amygdala with high-resolution MRI and three-dimensional analysis software: minimizing the discrepancies between laboratories. *Cereb Cortex* 2000;10:433–442.
24. Vaughan DN, Jackson GD. The piriform cortex and human focal epilepsy. *Front Neurol* 2014;5:259.
25. Goncalves Pereira PM, Insausti R, Artacho-Perula E, et al. MR volumetric analysis of the piriform cortex and cortical amygdala in drug-refractory temporal lobe epilepsy. *AJNR Am J Neuroradiol* 2005;26:319–332.
26. Wieser HG, Blume WT, Fish D, et al. ILAE Commission Report. Proposal for a new classification of outcome with respect to epileptic seizures following epilepsy surgery. *Epilepsia* 2001;42:282–286.
27. Helmstaedter C, Lendt M, Lux S. Verbaler Lern- und Merkfähigkeitstest: VLMT. Göttingen, Germany: Beltz Test, 2001.
28. Helmstaedter C, Pohl C, Hufnagel A, Elger CE. Visual learning deficits in nonresected patients with right temporal lobe epilepsy. *Cortex* 1991;27:547–555.
29. Lutz Mt, Helmstaedter C. EpiTrack: tracking cognitive side effects of medication on attention and executive functions in patients with epilepsy. *Epilepsy Behav* 2005;7(4):708–714.
30. Grote A, Witt J-A, Surges R, et al. A second chance—reoperation in patients with failed surgery for intractable epilepsy: long-term outcome, neuropsychology and complications. *J Neurol Neurosurg Psychiatry* 2016;87:379–385.
31. Clusmann H, Schramm J, Kral T, et al. Prognostic factors and outcome after different types of resection for temporal lobe epilepsy. *J Neurosurg* 2002;97:1131–1141.
32. Bonilha L, Keller SS. Quantitative MRI in refractory temporal lobe epilepsy: relationship with surgical outcomes. *Quant Imaging Med Surg* 2015;5:204–224.
33. Siegel AM, Wieser HG, Wichmann W, Yasargil GM. Relationships between MR-imaged total amount of tissue removed, resection scores of specific mediobasal limbic subcompartments and clinical outcome following selective amygdalohippocampectomy. *Epilepsy Res* 1990;6:56–65.
34. Wu C, Jermakowicz WJ, Chakravorti S, et al. Effects of surgical targeting in laser interstitial thermal therapy for mesial temporal lobe epilepsy: a multicenter study of 234 patients. *Epilepsia* 2019;60:1171–1183.
35. Sherman EM, Wiebe S, Fay-McClymont TB, et al. Neuropsychological outcomes after epilepsy surgery: systematic review and pooled estimates. *Epilepsia* 2011;52:857–869.
36. Doty RL, Tourbier I, Neff JK, et al. Influences of temporal lobe epilepsy and temporal lobe resection on olfaction. *J Neurol* 2018;265:1654–1665.
37. Stettler DD, Axel R. Representations of odor in the piriform cortex. *Neuron* 2009;63:854–864.
38. Koepp M, Galovic M. Functional imaging of the piriform cortex in focal epilepsy. *Exp Neurol* 2020;330:113305.
39. Roch C, Leroy C, Nehlig A, Namer IJ. Predictive value of cortical injury for the development of temporal lobe epilepsy in 21-day-old rats: an MRI approach using the lithium-pilocarpine model. *Epilepsia* 2002;43:1129–1136.
40. Roch C, Leroy C, Nehlig A, Namer IJ. Magnetic resonance imaging in the study of the lithium-pilocarpine model of temporal lobe epilepsy in adult rats. *Epilepsia* 2002;43:325–335.
41. Dube C, Boyet S, Marescaux C, Nehlig A. Progressive metabolic changes underlying the chronic reorganization of brain circuits during the silent phase of the lithium-pilocarpine model of epilepsy in the immature and adult rat. *Exp Neurol* 2000;162:146–157.
42. Honack D, Wahnschaffe U, Loscher W. Kindling from stimulation of a highly sensitive locus in the posterior part of the piriform cortex. Comparison with amygdala kindling and effects of antiepileptic drugs. *Brain Res* 1991;538:196–202.
43. Li S, Reinprecht I, Fahnestock M, Racine RJ. Activity-dependent changes in synaptophysin immunoreactivity in hippocampus, piriform cortex, and entorhinal cortex of the rat. *Neuroscience* 2002;115:1221–1229.

44. Racine RJ, Moore KA, Evans C. Kindling-induced potentiation in the piriform cortex. *Brain Res* 1991;556:218–225.
45. Vismar MS, Forcelli PA, Skopin MD, et al. The piriform, perirhinal, and entorhinal cortex in seizure generation. *Front Neural Circuits* 2015;9:27.
46. Heyer R, Dorr M, Jellen-Ritter A, et al. High throughput sequencing reveals a plethora of small RNAs including tRNA derived fragments in *Haloferax volcanii*. *RNA Biol* 2012;9:1011–1018.

## Supporting Information

Additional supporting information may be found online in the Supporting Information section at the end of the article.

**Table S1.** Table demonstrates the results of the volumetric analysis of tsSAHE target volumes in left-sided mTLE.

**Table S2.** Table demonstrates the results of the volumetric analysis of tsSAHE target volumes in right-sided mTLE.

### 3.5 Publication 5: Surgery for temporal lobe epilepsy in the elderly: Improving quality of life despite cognitive impairment





Contents lists available at ScienceDirect

## Seizure: European Journal of Epilepsy

journal homepage: [www.elsevier.com/locate/seizure](http://www.elsevier.com/locate/seizure)

## Surgery for temporal lobe epilepsy in the elderly: Improving quality of life despite cognitive impairment

Daniel Delev<sup>a,\*</sup>, Julia Taube<sup>b</sup>, Christoph Helmstaedter<sup>b</sup>, Karlijn Hakvoort<sup>a</sup>, Alexander Grote<sup>c</sup>, Hans Clusmann<sup>a,1</sup>, Marec von Lehe<sup>d,e,1</sup><sup>a</sup> Department of Neurosurgery, RWTH Aachen University, Aachen, Germany<sup>b</sup> Dept. of Epileptology, University of Bonn Medical Center, Bonn, Germany<sup>c</sup> Clinic for Neurosurgery, Evangelic Hospital of Bethel, Bielefeld, Germany<sup>d</sup> Department of Neurosurgery, Ruppiner Kliniken, Brandenburg Medical School, Neuruppin, Germany<sup>e</sup> Medical Faculty, University of Bonn Medical Center, Bonn, Germany

## ARTICLE INFO

## Keywords:

Epilepsy surgery  
Elderly  
Neuropsychology  
HRQOL  
Outcome

## ABSTRACT

**Introduction:** Temporal lobe epilepsy (TLE) surgery is still underutilized, especially in the elderly population because of concerns related to postoperative complication rate and cognitive deterioration. The aim of the study was to evaluate surgical data, quality of life and neuropsychological outcome in elderly patients, who underwent resective surgery for drug resistant TLE.

**Methods and materials:** All patients underwent standardized presurgical assessment including clinical, neuroradiological, neuropsychological, and EEG examination. Elderly were considered all patients being 50 years or above (mean 56 yr., range 50–71 yr.). Neuropsychology was assessed before and after surgery, health-related quality of life (HRQOL) only after surgery.

**Results:** A total of 94 consecutive elderly patients were analyzed. Temporo-mesial resections were performed in 85 patients (90 %). Seizure outcome was available in all patients with a mean follow-up of 5.2 years (1.2–19 ± 3.75 years). 57 patients (60.6 %) were completely seizure free (ILAE 1). The overall morbidity was 10 % including 5 surgical complications and 5 permanent neurological deficits. Neuropsychological assessments in 60 patients showed considerable preoperative impairment, losses in different domains in 25–45 % and gains in about 25 % of the patients. Postoperative HRQOL data was available in 75 patients, revealing significant increase of HRQOL in all domains. Complete seizure freedom was the strongest predictor for postoperative HRQOL ( $p < 0.001$ ).

**Conclusion:** Surgery for drug resistant temporal lobe epilepsy is a feasible option for elderly patients as seizure control rates are comparable to the younger population. The acceptable rate of permanent neurological deficits and relevant improvements in quality of life, despite considerable postoperative cognitive impairment, justify surgical resection in properly selected elderly patients.

## 1. Introduction

Epilepsy is one of the most common neurological diseases, leading to premature death, cognitive impairment and diminished quality of life [1,2]. About one third of all epilepsies are drug-resistant and surgery for drug-resistant focal epilepsy is safe and effective treatment option with proven better results than medical treatment in cases with temporal lobe epilepsy [3,4].

Epilepsy patients, who are scheduled for surgical treatment, are usually children or young adults without significant preoperative

morbidities. However, the incidence of newly diagnosed drug-resistant epilepsy in elderly is increasing and due to the recent demographic development, the number of potential candidates for surgical treatment in this subgroup is rising as well [5].

Despite these demographic changes and already established evidence regarding the effect of epilepsy surgery, resective treatment in elderly patients is still underutilized. The reluctance to surgery is mostly based on concerns regarding increased complication rates and more severe cognitive deterioration followed by a significant decrease of patients' quality of life. Additionally, long lasting epilepsy and older

\* Corresponding author at: Department of Neurosurgery, RWTH Aachen University, Aachen, Germany.

E-mail address: [ddelev@ukaachen.de](mailto:ddelev@ukaachen.de) (D. Delev).

<sup>1</sup> Contributed equally.

age have been shown to be a negative predictive factor associated with poor seizure outcome after epilepsy surgery. This implies that elderly patients would benefit less in terms of seizure outcome [6,7].

Recent publications comparing resective surgery in elderly and younger adults could however show that standardized epilepsy surgery procedures are not associated with significantly increased patient risk [8,9]. Additionally, some studies have shown stable neuropsychological outcomes after surgery in elderly [10]. Elderly patients are more vulnerable to the side effects of antiepileptic drugs (AEDs), present much higher risk for injuries after seizures and show higher mortality after prolonged seizures [11,12]. Meanwhile, this subgroup of patients is also becoming healthier with better manageable comorbidities [13], thus inevitably facing both neurosurgeons and epileptologists with the question, whether “age” alone is enough to withhold epilepsy surgery to the elderly population.

The outcomes of epilepsy surgery in the elderly has been poorly investigated until now. Although some studies have shown similar epileptological outcome to younger patients [5,8], the investigated cohorts included heterogeneous population of patients with temporal and extratemporal epilepsy and present no data in respect of the postoperative quality of life.

Here, we report a rather homogenous population cohort of 94 elderly patients (age  $\geq 50$  years), who underwent resective surgery for drug-resistant focal temporal lobe epilepsy. Additionally, we present long-term seizure outcome, data concerning postoperative health-related quality of life (HRQOL) and neuropsychological outcome. The main aim of the study was to provide data on elderly epilepsy surgery patients, analyze risk and benefit after resective surgery in terms of seizure outcome and quality of life, and to evaluate a potential risk for more severe cognitive long-term deterioration or surgical complications.

## 2. Methods

### 2.1. Study group

We identified 119 consecutive patients, who were 50 years or older and underwent resective surgery for drug-resistant temporal lobe epilepsy. Twenty-five patients did not fulfil the eligible criteria (extratemporal resections ( $n = 15$ ) and incomplete clinical or follow-up data ( $n = 10$ )) and were excluded from the study.

All patients ( $n = 94$ , 49 right-sided and 45 left-sided) had undergone presurgical assessment according to a standard protocol comprising clinical, neuroradiological, neuropsychological and EEG-data [14]. All preoperative images were reviewed during the interdisciplinary epilepsy conference. The preoperative imaging corresponded to specific epilepsy MRI protocols as described elsewhere [15].

The patients were assigned for the regular post-operative visits after three and twelve months. Follow-up information regarding seizure outcome (last available outcome, LAO) was obtained from the last regular yearly outpatient visit or from standardized telephone interviews. Some of the data was published previously [16].

### 2.2. Neuropsychological evaluation

Standardized neuropsychological assessment was conducted prior to and one year after epilepsy surgery. As previously described [17,18], the assessment focused on the evaluation of material-specific memory functions. To assess verbal learning and memory, the Verbaler Lern- und Merkfähigkeitstest (VLMT), an adaptation of the Rey Auditory Verbal Learning Test, was used. Patients had to learn a list of 15 words in 5 consecutive trials, which were followed by an interference trial, an immediate recall, a delayed recall and recognition. For the assessment of nonverbal learning and memory, the revised Diagnosticum für Cerebralschädigung (DCS-R) was administered. Patients had to learn 9 different figures over 5 trials, which were followed by a delayed recall

and recognition. Attention and executive functions were assessed by a German letter cancellation test (d2 Aufmerksamkeits- und Belastungstest), a response inhibition task (Kurztest für cerebrale Insuffizienz, ciT). Language was assessed with a phonemic fluency task, an object naming task (Boston Naming Test) and a verbal comprehension task (Token-Test). Visuospatial abilities were assessed with a mental rotation task (Subtest 7 of the “Leistungs-Prüfsystem”), the mazes of Chapuis, and the block design test of the Wechsler Scales (HAWIE-R). Detailed descriptions of the tests are provided in compendiums of neuropsychological tests.

Test results from each domain were summarized and classified into a five-point scale ranging from severely impaired to above average (0 = severe impairment (at least two test scores  $> 2$  SDs below the mean of the age-corrected normative sample; 1 = impairment, i.e. at least two test scores  $> 1$  SD below the mean; 2 = borderline, i.e. only one test score  $> 1$  SD below the mean; 3 = unimpaired, i.e. no test scores  $> 1$  SDs below the mean; 4 = above average, at least two test scores  $> 1$  SD above the mean) based on the underlying psychometric test results [19–21]. The distance between two subsequent categories approximately corresponds to one SD from the mean standardized score across all test scores of the respective domain. Neuropsychological change after surgery was defined as the intraindividual change in cognitive performance from pre- to postoperative assessment; the postoperative score was subtracted from the preoperative score in each domain. A positive value indicated improvement, a negative value indicated deterioration, a value of zero indicated no change.

### 2.3. Functional outcome

Neurological status was obtained for each patient at discharge and from the last regular annual outpatient visit. We used the term “temporary morbidity” when neurological deficits resolved until discharge or within 30 days. Deficits, which did not resolve after 30 days, were designated as “permanent morbidity”. Additionally, we analysed postoperative local and systemic complications during the 30-days period.

### 2.4. Health-related quality of life (HRQOL)

We routinely use a disease-specific questionnaire for assessing HRQOL [22]. In brief, the questionnaire addresses the postoperative self-assessed quality of life of the patients in four subdomains (physical function, cognitive function, mood, social interaction). An average result for the respective domain is calculated and these results are given as percentage of the maximum achievable value. Additionally, overall health-related quality of life is calculated by building the sum of the four subdomains, a self-assessment of “overall well-being” and “fear to experience another seizure”.

Patients are then asked to rate the postoperative changes compared to the presurgical status as better (+1), equal (0), or worse (-1). The results concerning changes after surgery are expressed as “trend values”, where positive values indicate average improvement and negative values mean deterioration. The last available seizure outcome (LAO) and the correlated quality of life data are obtained at the same time. The questionnaire is sent via mail and can be completed in approximately 15 min or is answered during a standardized telephone interview.

### 2.5. Seizure outcome

Seizure outcome was evaluated according to the ILAE classification [23]. ILAE 1 (completely seizure-free) has been referred to as excellent seizure outcome, whereas patients in ILAE class 1, 2 or 3 at the last available outcome (LAO) were classified as favorable outcome. The mean follow-up was 63 months (18–228 months).

## 2.6. Statistics

Statistical analysis was performed using a conventional Chi-square test for the categorical variables. Fisher exact test was used if sample sizes were  $< 5$  and the Mann-Whitney-U-Test for comparison of non-parametric values. Mean values of HRQOL domains were compared using two sample t-tests. A correlation model was created and tested for significance in order to examine the relationship between different HRQOL domains and neuropsychological categories. All tests were two-sided, and statistical significance was set at  $p \leq 0.05$ . 95 % confidential intervals (CIs) were used. All analyses were performed with SPSS software (BM Corp. Released 2011. IBM SPSS Statistics for Windows, Version 20.0. Armonk, NY: IBM Corp).

## 3. Results

### 3.1. Patient characteristics and demographical features

94 consecutive elderly patients (age  $> = 50$  years) were included. There were 44 (47 %) male patients. The mean age at surgery was 56 years (50–71,  $\pm 4.4$ ), while the mean duration of epilepsy was 31 years (1–62,  $\pm 15.7$ ). Temporo-mesial resections (including resection of amygdala and hippocampus) were performed in 85 patients (90 %), while the rest of the patients underwent temporo-lateral lesionectomies. The histopathological examination revealed 54 patients with hippocampus sclerosis, 12 patients with long-term epilepsy associated tumors (LEAT), 12 patients with cavernoma and 16 cases with hippocampal gliosis. Further demographic characteristics are presented on Table 1.

### 3.2. Seizure outcome

Seizure outcome was available in all 94 patients with a mean follow-up of 63 months (18–228,  $\pm 45$  months). At last available outcome a total of 75 (79 %) patients achieved favorable seizure outcome

**Table 1**

Patient cohort with corresponding histopathological results, complication rate and seizure outcome.

Patient characteristics	N	%
<b>Demographics</b>		
male	44	46.8%
female	50	53.2%
Age (Mean, Range) [yrs]	56 (50–71)	
Duration of epilepsy (Mean, Range) [yrs]	31 (1–62)	
Follow-up (Mean, Range) [mos]	63 (18–228)	
<b>Histopathological results</b>		
Hippocampal sclerosis	54	57.4%
Long-term epilepsy associated tumors (LEAT)	12	12.8%
Gliosis	16	17.3%
Cavernoma	12	12.8%
<b>Complications and deficits according to resection site</b>		
temporo-mesial		
systemic complication	2	2.0%
surgical complication	5	5.0%
temporary deficit	10	11.8 %
permanent deficit	5	5.9 %
temporo-lateral		
temporary deficit	1	1.0%
permanent deficit	0	0%
<b>ILAE</b>		
1	57	60.6 %
2	3	3.2%
3	15	16.0%
4	18	19.1%
5	1	1.1%

(ILAE1–3), and 57 (60.6 %) were completely seizure free (ILAE 1). The long-term seizure outcome showed stable results with a slight running-down phenomenon resulting in seizure free rates of 52 % (16 of 32 patients ILAE1) at 5 years after surgery. We found no statistical correlation between age of patients, duration of epilepsy, side or location of resection or histopathological results of the lesion and postoperative seizure control.

### 3.3. Complications and functional neurological outcome

There was no mortality. Two patients (2.1 %) showed systemic complications (one pulmonary embolism and one cardiac infarction), which were successfully managed but required extended hospitalization. There were 5 surgical complications (5.3 %) (CSF fistula in 3 patients and post-operative hemorrhage in 2 patients). Both systemic and surgical complications could be managed conservatively without resulting in permanent morbidity. Permanent neurological deficits (mild dysphasia (n = 2), aphasia (n = 1), mild hemiparesis (n = 3) and severe hemiparesis (n = 1)) were observed in five patients (5.9 %). Both severe complications (aphasia and severe hemiparesis) occurred in one patient, who suffered an infarction in the territory of the perforating vessels after a left-sided amygdalohippocampectomy. Eleven patients (11.8 %) encountered temporary neurological deficits (dysphasia in 7 patients and oculomotor nerve palsy in 4 patients) (Table 1), which resolved completely during the postoperative follow-up period. Thus, the overall permanent morbidity was 5.9 %. There was no correlation between patients' age and postoperative morbidity.

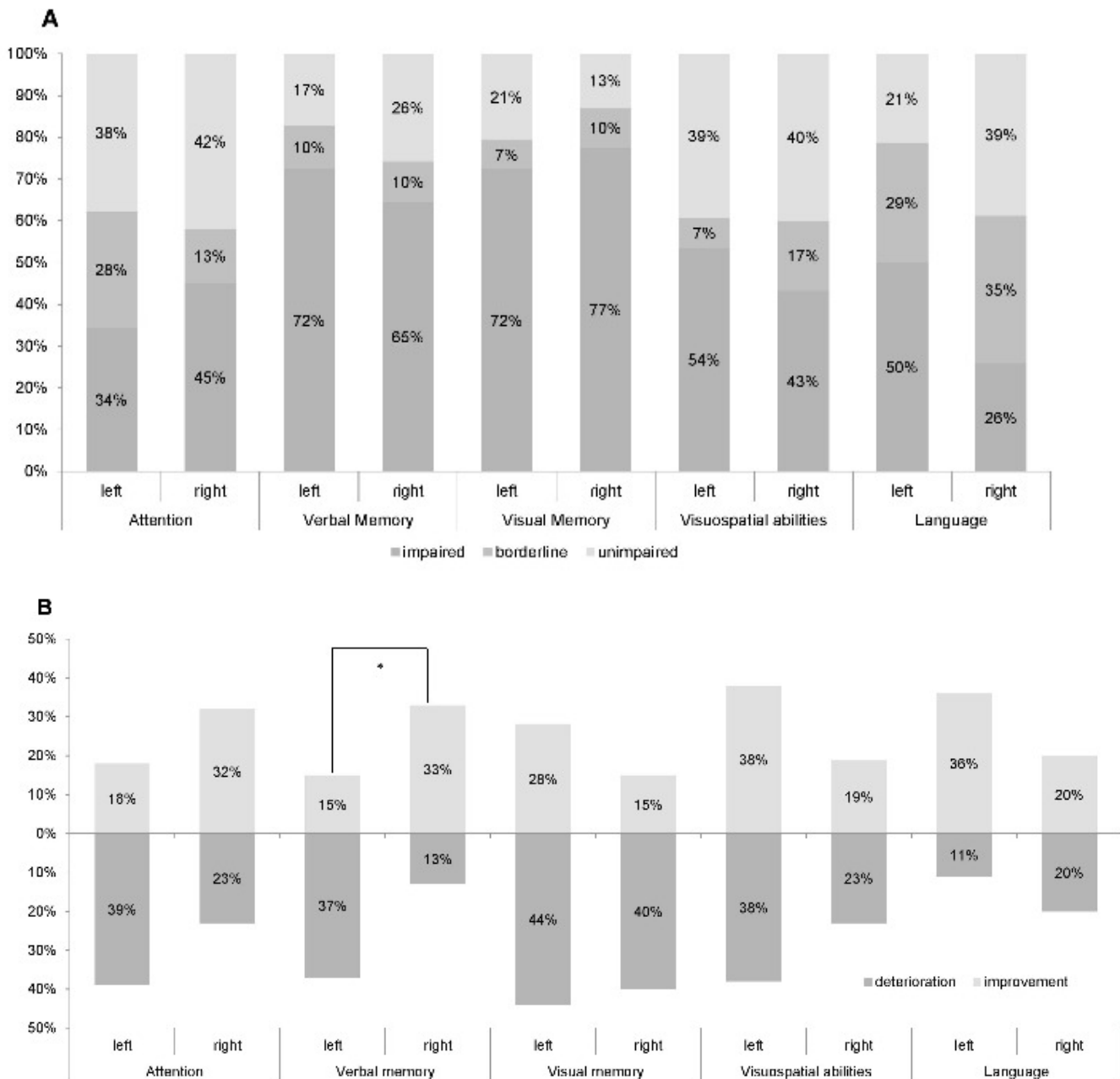
### 3.4. Neuropsychological outcome and post-operative health related quality of life (HRQOL)

Pre- and postoperative neuropsychological data were available in 60 patients (64 %, 29 females, 29 left-sided resections). The percentage of patients with impaired to severely impaired performance in at least one cognitive domain before surgery was 93 %. The rate of impairments per domain ranged from 37 % to 75 % (Fig. 1A). Visual memory was most frequently impaired (right: 77 %; left: 72 %), followed by verbal memory (right: 65 %; left: 72 %), attention (right: 45 %; left: 34 %) and language (right: 26 %; left: 50 %). Half of the patients had impaired visuospatial performance. There were no significant differences between the surgical sides. Postoperatively the percentages of impairments across domains remained the same. Postoperative course shows the number of patients with deteriorations and improvements in attention, language, visuospatial and memory functions for each surgical side (left vs right) (Fig. 1B). To account for floor and ceiling effects we excluded patients with severely impaired baseline performance and no losses from the analysis of losses and patients with excellent performance and no gains from the analysis of gains. With regard to verbal memory we excluded 3 patients; to visual memory 14; to visuospatial abilities and attention one, respectively, from the analysis of losses. There were no patients excluded with regard to ceiling effects.

Based on this approach, significant individual losses were most frequent in visual memory (42 %), followed by attention (30 %) and verbal memory (25 %). A similar proportion of 25 % of the patients improved in their performance across the different domains (Fig. 1B).

To assess cognitive change on the group level we used repeated-measures ANOVA and included postoperative seizure freedom (one year after surgery) and side of surgery into the model. A significant postoperative decline was shown for verbal memory ( $F(155) = 5.44$ ,  $p < .05$ ,  $\eta^2 = .09$ ). Patients performed significantly worse after left-sided resections. Visuospatial abilities improved after left-sided resections but not after right-sided resections ( $F(152) = 2.55$ ,  $p < .05$ ,  $\eta^2 = .10$ ). Changes in attention, language or visual memory did not reach significance ( $p = .08-.82$ ).

To assess cognitive change on the individual level we applied Chi-Square tests including the side of surgery for patients with significant



**Fig. 1.** A) Preoperative neuropsychological results for each cognitive domain and surgical side. B) Postoperative outcome in neuropsychological performance. Percentages were based on significant intraindividual changes from one category to another and were adjusted for floor and ceiling effects. Downward facing bars indicate deteriorations, upward facing bars indicate improvements. \*Significant differences between surgical side.

intraindividual decline, improvement or stable performance. None of the tests reached statistical significance ( $p = .07-.41$ ).

Postoperative health-related quality of life (HRQOL) data were available in 75 patients. The mean overall quality of life score was 51.81 points (from max 64 points, 76.2 %). The highest score was achieved in the domain “physical function” with 9.72 points (from max. 12 points, 81.2 %), whereas the lowest scores were obtained in the domain “cognitive function” with 10.91 points (from max. 16 points, 68.2 %) (Fig. 2A).

The self-rated postoperative changes (trend-value) showed positive values in all domains of HRQOL. Highest gains were found in “physical function” (0.38), while the least improvements were found for

“cognitive function” (0.07) (Fig. 2B)

Complete seizure freedom was significantly associated with higher scores in “overall HRQOL” ( $p < 0.001$ ) as well as in all subdomains (“social function” and “mood”  $p < 0.001$  respectively; “physical” and “cognitive function”:  $p = 0.01$  and  $p = 0.03$ , respectively) (Fig. 3A). The same result was obtained for the trend-values of overall HRQOL and all subdomains (Fig. 3B). Of note, the only deterioration after surgery in patients who did not become completely seizure (ILAE 2–5) was noted in the domain “cognitive function”.

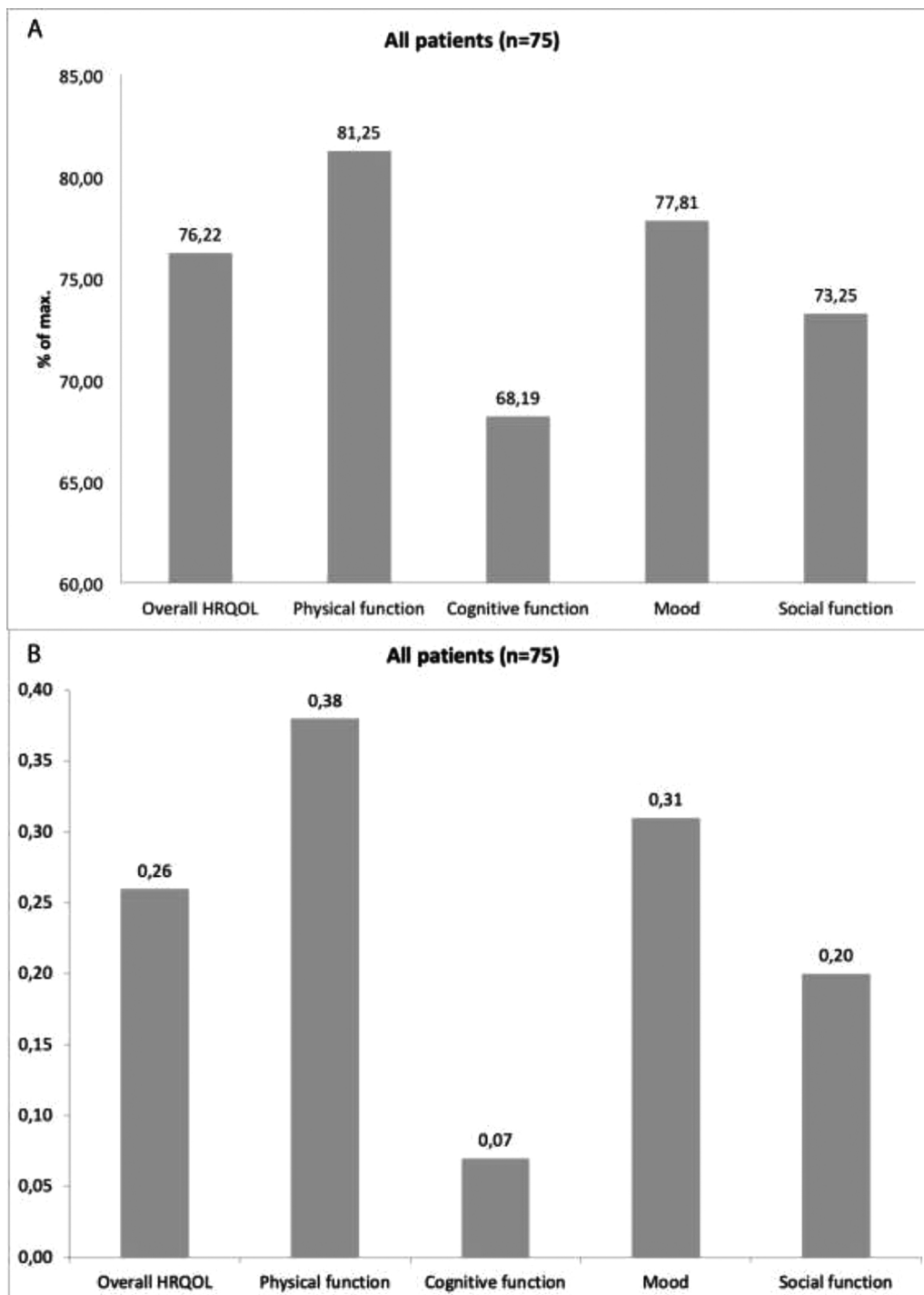


Fig. 2. A) Overall HRQOL and subdomains of HRQOL and B) post-operative changes (“trend-value”) of overall HRQOL and subdomains for all patients N = 75, Mean Follow-up: 65 months.

#### 4. Discussion

Resective surgery for drug resistant temporal lobe epilepsy is still controversially discussed when it comes to elderly patients. Two important risk factors influence the decision-making process – the risk of not becoming seizure free due to longer duration of epilepsy and the risk of higher complication rates or cognitive deterioration. Although some recent studies have showed good and stable seizure outcome [10,24] after resective procedures in elderly, the increased risk for surgical complications [25] and neuropsychological deterioration [26] hinders many physicians to submit older patients to presurgical

evaluation and surgery. Here, we address these questions by presenting seizure outcome results, complication rates and comprehensive data of neuropsychological and health-related quality of life evaluation in a rather homogeneous group of elderly patients with temporal lobe epilepsy.

In our cohort the final seizure outcome showed satisfactory results with 60.6 % seizure freedom after surgery. These results are in line with other series, reporting seizure-free rates in elderly patients ranging from 56 % to 78 % [8,9]. Despite the fact that most of the patients presented with relatively long duration of epilepsy (mean 31.8 years), the seizure outcome results remained favorable implying that at least in this

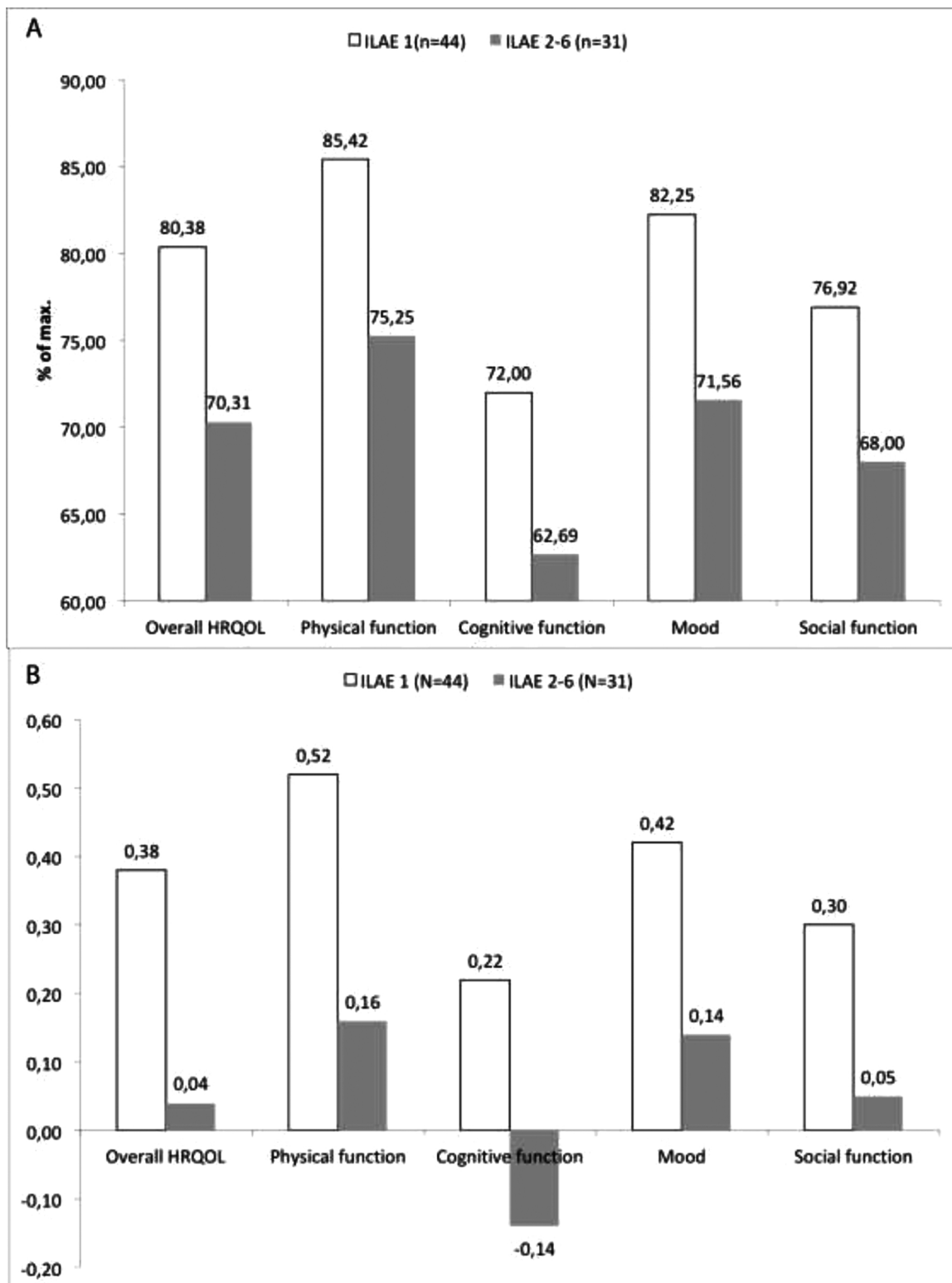


Fig. 3. A) Overall HRQOL and subdomains of HRQOL and B) post-operative changes ("trend-value") of overall HRQOL and subdomains in patients who were seizure-free (ILAE 1) vs. patients who continued to have seizures (ILAE 2-5). N = 75, Mean Follow-up: 65 months.

subpopulation epilepsy duration should not be seen as a contraindication for surgery. The overall morbidity rate (12.6 %) in this cohort was comparable with the data published from other series, reporting complications rates between 5% and 17 % [5,27]. The rate of permanent deficits (5%), however, was somewhat higher in comparison to the overall population (1.3 %–3 %) [28] but was in the same range as

reported by other series with elderly patients. Although severe neurological deficits occurred only in two patients (2%), the high overall permanent morbidity needs to be critically weighted against the benefits of the surgery (seizure freedom and improvements in HRQOL) during the decision-making process.

Another concern, which needs to be considered prior to a surgical



resection in elderly patients, is the possibility of neuropsychological deterioration, especially in patients undergoing temporo-mesial resections in the language dominant hemisphere. Normal preoperative neuropsychological results, absence of structural damage ipsilateral to surgery [29], older age at onset, longer duration of epilepsy and age at surgery are considered as risk factors for postoperative memory impairments. Since previous studies have described that patients with left TLE show a similar lifespan memory decline as the general population the remaining concern is whether surgery exacerbates age-related memory impairments [30–32].

In this study elderly patients showed poor to very poor performance levels remarkably often even before surgery. Taking this into consideration, it was verbal memory which nevertheless declined significantly after left-sided resections. Although the results were not statistically significant on the group or individual level, one third of the patients declined in figural memory. These results are in line with other studies reporting the neuropsychological outcome after epilepsy surgery in elderly [33]. Considering the poor baseline performance elderly patients still do have a risk of postoperative memory decline as seen in younger cohorts. This resembles the reported outcome of patients with bilateral hippocampal sclerosis, who despite their poor performance before surgery still showed significant postoperative memory decline.

An important aspect of this study is HRQOL data, which was available in 75 patients. HRQOL is increasingly considered as one of the major aspects for the evaluation of success after epilepsy surgery [22,34,35]. Satisfactory seizure outcome has been shown as major factor for improved HRQOL; some authors reported even “normalization” of HRQOL [36]. By reaching more than 75 % of the maximum value, our data showed satisfactory results concerning the overall HRQOL. Additionally, all trend values (self-assessed postoperative changes) remained positive after surgery (whole cohort) thus underlining the postoperative improvement of patients’ perceived quality of life. The domain with greatest improvement was the physical activity, while the cognitive domain showed only slight positive change. Only when seizure freedom could not be achieved, the self-reported cognitive change was reported as negative, in line with evaluation of the postoperative status.

Another important finding of this work is the lacking correlation between neuropsychological outcomes and HRQOL suggesting that the neuropsychological deterioration did not significantly influence patients’ quality of life. A possible explanation for this phenomenon could be the fact that elderly showed significant neuropsychological deficits already prior to surgery. Furthermore, most of those patients were already retired and integrated in protective social surrounding making the demands at the neuropsychological performance less extensive. In contrast, seizure freedom and neurological status gain importance exactly in such social surrounding, which explains the relatively high postoperative HRQOL scores in older patients.

Our study has some limitations. Firstly, this is a single-center cohort study potentially leading to a relevant bias in terms of patient selection. Data analysis was performed retrospectively, and the sample size may limit proper analysis in some subgroups. However, due to the standardized surgical procedures, long follow-up and low dropout rate, as well as evaluation of both HRQOL and neuropsychological outcomes, this retrospective series provides concise and valuable information about a homogenous group of older patients with TLE. Nevertheless, the main goal of future investigations should be the generation of prospective studies thus providing data with stronger evidence.

## 5. Conclusion

Surgery for drug resistant temporal lobe epilepsy is feasible option for elderly patients. Although this subpopulation is characterized by longer duration of epilepsy and poor baseline cognition, the chance for becoming seizure free are as high as in the younger population. Despite a higher rate of permanent neurological deficits and neuropsychological

decline, seizure control and relevant improvements in quality of life justify surgical resection in properly selected elderly patients.

## Declaration of interest

None.

## Funding source

This research did not receive any specific grant from funding agencies in the public, commercial, or not-for-profit sectors.

## References

- [1] Baker GA, Jacoby A, Buck D, Stalgis C, Monnet D. Quality of life of people with epilepsy: a European study. *Epilepsia* 1997;38:353–62. <https://doi.org/10.1111/j.1528-1157.1997.tb01128.x>.
- [2] Baker GA, Nashif L, Hout BA. Current issues in the management of epilepsy: the impact of frequent seizures on cost of illness, quality of life, and mortality. *Epilepsia* 1997;38:S1–8. <https://doi.org/10.1111/j.1528-1157.1997.tb04511.x>.
- [3] Wiebe S, Blume WT, Girvin JP, Eliasziw M, Group E and E of S for TLES. A randomized, controlled trial of surgery for temporal-lobe epilepsy. *New Engl J Med Surg Collat Branches Sci* 2001;345:311–8. <https://doi.org/10.1056/nejm200108023450501>.
- [4] Wiebe S. Outcome patterns in epilepsy surgery—the long-term view. *Nat Rev Neurol* 2012;8:123–4. <https://doi.org/10.1038/nrneurol.2012.9>.
- [5] Lang JD, Grell L, Hagge M, Onugoren MD, Gollwitzer S, Graf W, et al. Long-term outcome after epilepsy surgery in older adults. *Seizure* 2018;57:56–62. <https://doi.org/10.1016/j.seizure.2018.02.012>.
- [6] Meguins LC, Adry RAR da C, Silva-Junior SC da, Filho GM de A, Marques LHN. Shorter epilepsy duration is associated with better seizure outcome in temporal lobe epilepsy surgery. *Arq Neuro-Psiquiat* 2015;73:212–7. <https://doi.org/10.1590/0004-282x20140230>.
- [7] Jeong S, Lee SK, Hong K, Kim K, Chung C, Kim H. Prognostic factors for the surgery for mesial temporal lobe epilepsy: longitudinal analysis. *Epilepsia* 2005;46:1273–9. <https://doi.org/10.1111/j.1528-1167.2005.33504.x>.
- [8] Bialek F, Rydenhag B, Flink R, Malmgren K. Outcomes after resective epilepsy surgery in patients over 50 years of age in Sweden 1990–2009 – A prospective longitudinal study. *Seizure* 2014;23:641–5. <https://doi.org/10.1016/j.seizure.2014.05.003>.
- [9] Punia V, Abdelkader A, Busch RM, Gonzalez-Martinez J, Bingaman W, Najm I, et al. Time to push the age limit: epilepsy surgery in patients 60 years or older. *Epilepsia Open* 2018;3:73–80. <https://doi.org/10.1002/epi4.12099>.
- [10] Chapin JS, Busch RM, Silveira DC, Wehner T, Naugle RI, Ferguson L, et al. Memory Performance in Older Adults Before and After Temporal Lobectomy for Pharmacoresistant Epilepsy. *Clin Neuropsychologist* 2013;27:1316–27. <https://doi.org/10.1080/13854046.2013.850535>.
- [11] Perucca E, Berlowitz D, Birnbaum A, Cloyd JC, Garrard J, Hanlon JT, et al. Pharmacological and clinical aspects of antiepileptic drug use in the elderly. *Epilepsy Res* 2006;68:49–63. <https://doi.org/10.1016/j.epilepsyres.2005.07.017>.
- [12] Brodie MJ, Stephen LJ. International review of neurobiology. *Int Rev Neurobiol* 2007;81:253–63. [https://doi.org/10.1016/s0074-7742\(06\)81016-0](https://doi.org/10.1016/s0074-7742(06)81016-0).
- [13] Crimmins EM. Trends in the health of the elderly. *Annu Rev Publ Health* 2004;25:79–98. <https://doi.org/10.1146/annurev.publhealth.25.102802.124401>.
- [14] Kral T, Clusmann H, Urbach J, Schramm J, Elger CE, Kurthen M, et al. Preoperative evaluation for epilepsy surgery (Bonn algorithm). *Zentralblatt Für Neurochir* 2002;63:106–10. <https://doi.org/10.1055/s-2002-35826>.
- [15] Wellmer J, Quesada CM, Rothe L, Elger CE, Bien CG, Urbach H. Proposal for a magnetic resonance imaging protocol for the detection of epileptogenic lesions at early outpatient stages. *Epilepsia* 2013;54:1977–87. <https://doi.org/10.1111/epi.12375>.
- [16] Grivas A, Schramm J, Kral T, Lehe MV, Helmstaedter C, Elger CE, et al. Surgical treatment for refractory temporal lobe epilepsy in the elderly: seizure outcome and neuropsychological sequelae compared with a younger cohort. *Epilepsia* 2006;47:1364–72. <https://doi.org/10.1111/j.1528-1167.2006.00608.x>.
- [17] Helmstaedter C, Petzold I, Bien CG. The cognitive consequence of resecting non-lesional tissues in epilepsy surgery—results from MRI- and histopathology-negative patients with temporal lobe epilepsy. *Epilepsia* 2011;52:1402–8. <https://doi.org/10.1111/j.1528-1167.2011.03157.x>.
- [18] Vogt VL, Witt J-A-A, Malter MP, Schoene-Bake J-C-C, Lehe MV, Elger CE, et al. Neuropsychological outcome after epilepsy surgery in patients with bilateral Ammon’s horn sclerosis. *J Neurosurg* 2014;121:1247–56. <https://doi.org/10.3171/2014.7.jns132037>.
- [19] Grote A, Witt J-A-A, Surges R, Lehe MV, Pieper M, Elger CE, et al. A second chance—reoperation in patients with failed surgery for intractable epilepsy: long-term outcome, neuropsychology and complications. *J Neurology Neurosurg Psychiatry* 2016;87:379. <https://doi.org/10.1136/jnnp-2015-310322>.
- [20] Clusmann H, Schramm J, Kral T, Helmstaedter C, Ostertun B, Fimmers R, et al. Prognostic factors and outcome after different types of resection for temporal lobe epilepsy. *J Neurosurg* 2002;97:1131–41. <https://doi.org/10.3171/jns.2002.97.5.1131>.

- [21] Helmstaedter C, Witt J. Multifactorial etiology of interictal behavior in frontal and temporal lobe epilepsy. *Epilepsia* 2012;53:1765–73. <https://doi.org/10.1111/j.1528-1167.2012.03602.x>.
- [22] Lehe MV, Lutz M, Kral T, Schramm J, Elger CE, Clusmann H. Correlation of health-related quality of life after surgery for mesial temporal lobe epilepsy with two seizure outcome scales. *Epilepsy Behav* 2006;9:73–82. <https://doi.org/10.1016/j.yebeh.2006.03.014>.
- [23] 1997-2001: C on N of the ILAE (ILAE), Wieser HG, Blume WT, Fish D, Goldensohn E, Hufnagel A, et al. Proposal for a new classification of outcome with respect to epileptic seizures following epilepsy surgery. *Epilepsia* 2008;42:282–6. <https://doi.org/10.1046/j.1528-1157.2001.35100.x>.
- [24] Dewar S, Eliashiv D, Walshaw PD, Engel J, Fried I, Moseley BD. Safety, efficacy, and life satisfaction following epilepsy surgery in patients aged 60 years and older. *J Neurosurg* 2016;124:945–51. <https://doi.org/10.3171/2015.3.jns142317>.
- [25] Srikijvilaikul T, Lerdlum S, Tepmongkol S, Shuangshoti S, Locharnkul C. Outcome of temporal lobectomy for hippocampal sclerosis in older patients. *Seizure* 2011;20:276–9. <https://doi.org/10.1016/j.seizure.2010.12.008>.
- [26] Thompson PJ, Baxendale SA, McEvoy AW, Duncan JS. Cognitive outcomes of temporal lobe epilepsy surgery in older patients. *Seizure* 2015;29:41–5. <https://doi.org/10.1016/j.seizure.2015.03.017>.
- [27] Moura LMVR, Eskandar EN, Hassan M, Salinas J, Cole AJ, Hoch DB, et al. Anterior temporal lobectomy for older adults with mesial temporal sclerosis. *Epilepsy Res* 2016;127:358–65. <https://doi.org/10.1016/j.eplepsyres.2016.09.021>.
- [28] Rydenhag B, Silander HC. Complications of epilepsy surgery after 654 procedures in Sweden, September 1990–1995: a multicenter study based on the Swedish national epilepsy surgery register. *Neurosurgery* 2001;49:51. <https://doi.org/10.1097/00006123-200107000-00007>.
- [29] Witt J-A-A, Coras R, Schramm J, Becker AJ, Elger CE, Blümcke I, et al. The overall pathological status of the left hippocampus determines preoperative verbal memory performance in left mesial temporal lobe epilepsy: hippocampal Neuronal Cell Densities and Memory Functions. *Hippocampus* 2013;24:446–54. <https://doi.org/10.1002/hipo.22238>.
- [30] Helmstaedter C, Kurthen M, Lux S, Reuber M, Elger CE. Chronic epilepsy and cognition: a longitudinal study in temporal lobe epilepsy. *Ann Neurol* 2003;54:425–32. <https://doi.org/10.1002/ana.10692>.
- [31] Helmstaedter C, Elger CE. Chronic temporal lobe epilepsy: a neurodevelopmental or progressively dementing disease? *Brain* 2009;132:2822–30. <https://doi.org/10.1093/brain/awp182>.
- [32] Helmstaedter C, Elger C. The phantom of progressive dementia in epilepsy. *Lancet* 1999;354:2133–4. [https://doi.org/10.1016/s0140-6736\(99\)03542-4](https://doi.org/10.1016/s0140-6736(99)03542-4).
- [33] Helmstaedter C, Reuber M, Elger CCE. Interaction of cognitive aging and memory deficits related to epilepsy surgery. *Ann Neurol* 2002;52:89–94. <https://doi.org/10.1002/ana.10260>.
- [34] Sajobi TT, Fiest KM, Wiebe S. Changes in quality of life after epilepsy surgery: the role of reprioritization response shift. *Epilepsia* 2014;55:1331–8. <https://doi.org/10.1111/epi.12697>.
- [35] Kellett MW, Smith DF, Baker GA, Chadwick DW. Quality of life after epilepsy surgery. *J Neurology Neurosurg Psychiatry* 1997;63:52. <https://doi.org/10.1136/jnnp.63.1.52>.
- [36] Mikati MA, Comair YG, Rahi A. Normalization of quality of life three years after temporal lobectomy: a controlled study. *Epilepsia* 2006;47:928–33. <https://doi.org/10.1111/j.1528-1167.2006.00523.x>.

## 4 Discussion

This thesis investigated the contributions of different epilepsy- and surgery-related factors on the postoperative seizure and cognitive outcome in patients who underwent TLS for the treatment of refractory TLE. More specifically, the present studies focused on the histopathological diagnosis of GO in comparison to HS, resection of the piriform cortex as a hub for epileptic circuits in TLE, and finally, risks and chances of TLS in late adulthood.

### 4.1 Summary and outlook

The first study (Borger et al., 2021a) retrospectively analyzed a large consecutive cohort of 161 patients with refractory TLE who underwent TLS at the University Hospital Bonn. 75% of these patients were seizure-free one year after surgery, which is consistent with previously reported outcomes (Lamberink et al., 2020). It is important to note that we found similar seizure outcomes for sAHE and ATL in our study sample. This is because ATL was only indicated in our epilepsy center if lateral temporal regions were marked as epileptogenic or pathological during the presurgical evaluation. In contrast, sAHE was the standard approach when seizure origin was strictly mesial (Schramm, 2008).

We found a fivefold increase in risk of seizure recurrence after surgery associated with the histopathological diagnosis of GO, a finding that has not been reported previously. This result questions the current classification of GO resembling a predecessor of HS instead of a distinct clinical entity.

Regarding the neuropsychological outcome, we were able to replicate previous findings of verbal memory decline following left TLS and visual (non-verbal) memory decline following right TLS. Therefore, laterality, as previously shown, remains one of the most important predictors of postoperative cognitive changes (Lee, Yip, & Jones-Gotman, 2002). This is one of the first studies to demonstrate the clinical utility of applying global domain-specific cognitive scores, otherwise termed cognitive phenotypes (Hermann et al., 2007), derived from different sub-

tests, i.e., verbal memory derived from verbal learning, loss, free recall, and recognition. Different from a study by Baxendale & Thompson (2020), domain-specific cognitive scores were sensitive towards not only preoperative impairments but also postoperative changes in patients who underwent TLS for the treatment of intractable seizures originating in the TL. This approach may facilitate the comparison of neuropsychological outcomes across different epilepsy centers even though the applied tests and subtests remain heterogeneous (Vogt et al., 2017).

Following these findings, the second (Grote et al., 2022) and third study (Taube et al., 2022) investigated patients with the histopathological diagnosis of GO in more detail. Clinical, neuropathological, and neuropsychological data were systematically analyzed and compared to patients with HS in a consecutive cohort of 627 patients. The neuropsychological analysis focused on a matched case-control sample of 98 patients. Transcriptional analysis was performed in 24 histological specimens.

Previous histopathological hallmarks suggestive of a strikingly different neuron-to-glia ratio could be confirmed (Blümcke et al., 2007; Blumcke et al., 2013). However, both studies, refuting previous assumptions, strongly indicate that GO and HS represent distinct clinical entities. The later epilepsy onset associated with GO argues against the assumption that it is simply a predecessor of HS before the onset of neuronal cell loss in the hippocampal subfields. It was also significantly less treatable by surgery, i.e., seizure outcome was favorable for only 43% of GO patients but for 68% of HS patients. The transcriptional analysis identified 265 genes differentiating between GO and HS and upregulated proteins resembling an innate chronic inflammatory state of reactive astrocytes in GO but not HS, a completely new finding. This led to the new term 'innate inflammatory gliosis only'.

On a functional level, patients with GO were having less frequent, less severe, and more non-specific cognitive impairments before surgery, both on a domain-specific level and on individual test scores. This result is in line with previous studies highlighting the dependence of memory processes on the structural integrity of the hippocampus to be resected (Chelune, 1995; Hermann et al., 1992; Witt et al., 2014a). As expected, cognitive decline after TLS was more pronounced in

patients with GO with a two- to threefold increased risk of disproportionate large cognitive losses.

In summary, these results emphasize that epilepsy surgery should be offered with great caution to patients with suspected GO due to the worse postoperative seizure outcome and high cognitive costs. The underlying inflammatory pathomechanisms, even though further investigations are required to underpin our findings, may even argue against a surgical approach in these patients. Based on these results, we propose that underlying inflammation should be suspected and evaluated at the onset of TLE, as it may result in a different therapeutic regimen, possibly even disrupting epileptogenesis in the first place.

The fourth study (Borger et al., 2021b) was conducted to investigate the PIC as a surgical target structure in selective TLS. A subset of patients from the first study was volumetrically (hippocampus, amygdala, and PIC) and neuropsychologically assessed and divided into two seizure outcome groups following sAHE. The resection extent of PIC was significantly larger in the seizure-free group. Hippocampal or amygdala resection volumes did not differ between the groups. These results are in line with other studies, which have established close associations between increased PIC resection and improved seizure outcome (Koepp et al., 2019; Leon-Rojas et al., 2021). In our cohort, seizure outcome was better when more than 27% of the temporal PIC was resected. While this study further supports the notion that the PIC is an important hub involved in the epileptic network of TLE, further research needs to investigate how residual epileptic circuits may contribute to postoperative seizure recurrence.

On a functional level, a larger PIC resection did not lead to larger cognitive decrements after surgery, which is in line with previous research (Koepp et al., 2019). This study was the first to evaluate attention and language outcomes depending on the PIC resection. There was a marginally significant effect implying that attention improved with increased PIC resection, which was possibly related to better seizure outcomes and an associated reduction or withdrawal from ASM. However, the functional consequences of resection need further investigation. Even though it is part of the olfactory neuronal network, outcomes regarding odor identification, discrimination, and odor memory have not yet been investigated

(Hwang et al., 2020). Future studies need to address whether pathology inherent in PIC can be linked to olfactory impairment, i.e., lateralization and localization of the epileptogenic network and whether resection leads to decrements in olfactory function as a surrogate marker for the postoperative outcome.

Prospective studies will also have to determine the risks and benefits of surgical resection of PIC in a standardized procedure, as it is a surgically challenging target structure because it is indistinct in humans and surrounds the M1 portion of the middle cerebral artery and its lenticulostriate branches (Leon-Rojas et al., 2021).

Finally, the fifth study (Delev et al., 2020) investigated whether TLS in the elderly was associated with more neurological adverse events, an increased risk of memory decline, and negative health-related quality of life. Of the 94 patients, 50 years of age or above, 61% were completely seizure-free after surgery. Even though losses in neuropsychological performance were evident in up to 45% of the patients, health-related quality of life improved. Hence, TLS in the elderly can be considered as a safe and effective treatment option.

However, our results provide support for the assumption that accelerated aging is a major concern in this age group. As expected, impairments were severe before surgery. Additionally, TLS accentuated previous cognitive problems in almost half of the patients, which may put them at an increased risk of reaching a critical threshold of memory impairment with incapacitating consequences for daily life (Sen et al., 2018; Witt et al., 2014b).

## 4.2 Conclusion

While epilepsy surgery can be considered a safe treatment option for drug-resistant TLE across the lifespan, several risk factors for an unfavorable seizure and cognitive outcome became evident, which may lead to significant changes in the treatment of TLE. We propose an early evaluation of inflammatory and neurodegenerative biomarkers (CSF, imaging, etc.) in patients with new-onset or late-onset TLE. Epilepsy surgery should be offered with greater caution when neuropsychological performance is normal or only mildly impaired, even though the ques-



tion about critical thresholds of when cognitive decline results in functional impairment in daily life remains unanswered. Even though the PIC was identified as a promising target of TLS, further research is needed to improve our understanding of how residual epileptic networks contribute to seizure recurrence. Therefore, this thesis adds to our current knowledge about the risks and benefits for patients undergoing surgical treatment of refractory TLE with significant implications for pre-operative decision-making and counseling to improve individual medical care.

## 5 References

- Bell ML, Rao S, So EL, Trenerry M, Kazemi N, Stead SM, Cascino G, Marsh R, Meyer FB, Watson RE, Giannini C, Worrell GA. Epilepsy surgery outcomes in temporal lobe epilepsy with a normal MRI. *Epilepsia* 2009. 50: 2053–2060 .
- de Bézenac CE, Adan G, Weber B, Keller SS. Association of Epilepsy Surgery With Changes in Imaging-Defined Brain Age. 2021. 97: 554–563 .
- Blumcke I, Cross JH, Spreafico R. The international consensus classification for hippocampal sclerosis: An important step towards accurate prognosis. *The Lancet Neurology* 2013. 12: 844–846 .
- Blümcke I, Pauli E, Clusmann H, Schramm J, Becker A, Elger C, Merschhemke M, Meencke HJ, Lehmann T, von Deimling A, Scheiwe C, Zentner J, Volk B, Romstöck J, Stefan H, Hildebrandt M. A new clinico-pathological classification system for mesial temporal sclerosis. *Acta Neuropathologica* 2007. 113: 235–244 .
- Borger V, Hamed M, Taube J, Aydin G, Ilic I, Schneider M, Schuss P, Güresir E, Becker A, Helmstaedter C, Elger CE, Vatter H. Resective temporal lobe surgery in refractory temporal lobe epilepsy: prognostic factors of postoperative seizure outcome. *J Neurosurg* 2021a. 135: 760–769 .
- Borger V, Schneider M, Taube J, Potthoff AL, Keil VC, Hamed M, Aydin G, Ilic I, Solymosi L, Elger CE, Güresir E, Fimmers R, Schuss P, Helmstaedter C, Surges R, Vatter H. Resection of piriform cortex predicts seizure freedom in temporal lobe epilepsy. *Annals of Clinical and Translational Neurology* 2021b. 8: 177–189 .
- Chee K, Razmara A, Geller AS, Harris WB, Restrepo D, Thompson JA, Kramer DR. The role of the piriform cortex in temporal lobe epilepsy: A current literature review. *Frontiers in Neurology* 2022. 0: 2669 .
- Chelune GJ. Hippocampal adequacy versus functional reserve: Predicting memory functions following temporal lobectomy. *Archives of Clinical Neuropsychology* 1995. 10: 413–432 .
- Cheng H, Wang Y, Chen J, Chen Z. The piriform cortex in epilepsy: What we learn from the kindling model. *Experimental neurology* 2020. 324: 113137 .

- Clusmann H, Schramm J, Kral T, Helmstaedter C, Ostertun B, Fimmers R, Haun D, Elger CE. Prognostic factors and outcome after different types of resection for temporal lobe epilepsy. *Journal of neurosurgery* 2002. 97: 1131–41 .
- Cook C, Baxendale S. Preoperative predictors of postoperative satisfaction with surgery. *Epilepsy & Behavior* 2022. 129: 108612 .
- Delev D, Taube J, Helmstaedter C, Hakvoort K, Grote A, Clusmann H, Lehe M von. Surgery for temporal lobe epilepsy in the elderly: Improving quality of life despite cognitive impairment. *Seizure* 2020. 79: 112–119 .
- Engel JJ. The current place of epilepsy surgery. *Current opinion in neurology* 2018. 31: 192–197 .
- Engel J, Wiebe S, French J, Sperling M, Williamson P, Spencer D, Gumnit R, Zahn C, Westbrook E, Enos B. Practice Parameter: Temporal Lobe and Localized Neocortical Resections for Epilepsy. *Epilepsia* 2003. 44: 741–751 .
- Farina C, Aloisi F, Meinl E. Astrocytes are active players in cerebral innate immunity. *Trends in Immunology* 2007. 28: 138–145 .
- Fisher RS, Acevedo C, Arzimanoglou A, Bogacz A, Cross JH, Elger CE, Engel JJ, Forsgren L, French JA, Glynn M, Hesdorffer DC, Lee BI, Mathern GW, Moshé SL, Perucca E, Scheffer IE, Tomson T, Watanabe M, Wiebe S. ILAE official report: a practical clinical definition of epilepsy. *Epilepsia* 2014. 55: 475–482 .
- Gallo B v. Epilepsy, surgery, and the elderly. *Epilepsy Research*. Elsevier, 83–86.
- Gargaro AC, Sakamoto AC, Bianchin MM, Geraldi C de VL, Scorsi-Rosset S, Coimbra ÉR, Carlotti CG, Assirati JA, Velasco TR. Atypical neuropsychological profiles and cognitive outcome in mesial temporal lobe epilepsy. *Epilepsy & Behavior* 2013. 27: 461–469 .
- Gleissner U, Helmstaedter C, Elger CE. Right hippocampal contribution to visual memory: a presurgical and postsurgical study in patients with temporal lobe epilepsy. *Journal of neurology, neurosurgery, and psychiatry* 1998. 65: 665–669 .
- Gleissner U, Helmstaedter C, Schramm J, Elger CE. Memory Outcome after Selective Amygdalohippocampectomy in Patients with Temporal Lobe Epilepsy: One-year Follow-up. *Epilepsia* 2004. 45: 960–962 .
- Grivas A, Schramm J, Kral T, von Lehe M, Helmstaedter C, Elger CE, Clusmann H. Surgical treatment for refractory temporal lobe epilepsy in the elderly: Seizure outcome

- and neuropsychological sequels compared with a younger cohort. *Epilepsia* 2006. 47: 1364–1372 .
- Grote A, Heiland DH, Taube J, Helmstaedter C, Ravi VM, Will P, Hattingen E, Schüre JR, Witt JA, Reimers A, Elger C, Schramm J, Becker AJ, Delev D. ‘Hippocampal innate inflammatory gliosis only’ in pharmaco-resistant temporal lobe epilepsy. *Brain* 2022.
- Hattingen E, Enkirch SJ, Jurcoane A, Kruse M, Delev D, Grote A, Becker A. Hippocampal “gliosis only” on MR imaging represents a distinct entity in epilepsy patients. *Neuroradiology* 2018. 60: 161–168 .
- Helmstaedter C. Neuropsychological aspects of epilepsy surgery. *Epilepsy & Behavior* 2004. 5: 45–55 .
- Helmstaedter C. Cognitive outcomes of different surgical approaches in temporal lobe epilepsy. *Epileptic disorders : international epilepsy journal with videotape* 2013. 15: 221–39 .
- Helmstaedter C, Grunwald T, Lehnertz K, Gleissner U, Elger CE. Differential involvement of left temporolateral and temporomesial structures in verbal declarative learning and memory: evidence from temporal lobe epilepsy. *Brain and cognition* 1997. 35: 110–131 .
- Helmstaedter C, Kemper B, Elger CE. Neuropsychological aspects of frontal lobe epilepsy. *Neuropsychologia* 1996. 34: 399–406 .
- Helmstaedter C, Kurthen M, Lux S, Reuber M, Elger CE. Chronic epilepsy and cognition: A longitudinal study in temporal lobe epilepsy. *Annals of Neurology* 2003. 54: 425–432 .
- Helmstaedter C, Petzold I, Bien CG. The cognitive consequence of resecting nonlesional tissues in epilepsy surgery—Results from MRI- and histopathology-negative patients with temporal lobe epilepsy. *Epilepsia* 2011. 52: 1402–1408 .
- Helmstaedter C, Richter S, Röske S, Oltmanns F, Schramm J, Lehmann TN. Differential effects of temporal pole resection with amygdalohippocampectomy versus selective amygdalohippocampectomy on material-specific memory in patients with mesial temporal lobe epilepsy. *Epilepsia* 2008. 49: 88–97 .
- Helmstaedter C, van Roost D, Clusmann H, Urbach H, Elger CE, Schramm J. Collateral brain damage, a potential source of cognitive impairment after selective surgery for

- control of mesial temporal lobe epilepsy. *Journal of neurology, neurosurgery, and psychiatry* 2004. 75: 323–6 .
- Helmstaedter C, Witt JA. Multifactorial etiology of interictal behavior in frontal and temporal lobe epilepsy. *Epilepsia* 2012. 53: 1765–1773 .
- Helmstaedter C, Witt JA. Epilepsy and cognition - A bidirectional relationship? *Seizure* 2017. 49: 83–89 .
- Hermann B, Seidenberg M, Lee EJ, Chan F, Rutecki P. Cognitive phenotypes in temporal lobe epilepsy. *Journal of the International Neuropsychological Society* 2007. 13: 12–20 .
- Hermann BP, Wyler AR, Somes G, Berry AD, Dohan FC. Pathological status of the mesial temporal lobe predicts memory outcome from left anterior temporal lobectomy. *Neurosurgery* 1992. 31: 652–657 .
- Hwang BY, Mampre D, Penn R, Anderson WS, Kang J, Kamath V. Olfactory Testing in Temporal Lobe Epilepsy: a Systematic Review. *Current Neurology and Neuroscience Reports* 2020. 20.
- Jobst BC, Cascino GD. Resective Epilepsy Surgery for Drug-Resistant Focal Epilepsy: A Review. *JAMA* 2015. 313: 285–293 .
- Koepp M, Galovic M. Functional imaging of the piriform cortex in focal epilepsy. *Experimental Neurology* 2020. 330: 113305 .
- Koepp MJ, Galovic M, Baudracco I, Wright-Goff E, Pillajo G, Nachev P, Wandschneider B, Woermann F, Thompson P, Baxendale S, McEvoy AW, Nowell M, Mancini M, Vos SB, Winston GP, Sparks R, Prados F, Miserocchi A, de Tisi J, van Graan LA, Rodionov R, Wu C, Alizadeh M, Kozlowski L, Sharan AD, Kini LG, Davis KA, Litt B, Ourselin S, Moshé SL, Sander JWA, Löscher W, Duncan JS. Association of Piriform Cortex Resection With Surgical Outcomes in Patients With Temporal Lobe Epilepsy. *JAMA Neurology* 2019. 76: 690 .
- Koubeissi MZ. Editorial: The piriform cortex in epilepsy. *Experimental Neurology* 2020. 329: 113313 .
- Kwan P, Arzimanoglou A, Berg AT, Brodie MJ, Allen Hauser W, Mathern G, Moshé SL, Perucca E, Wiebe S, French J. Definition of drug resistant epilepsy: consensus proposal by the ad hoc Task Force of the ILAE Commission on Therapeutic Strategies. *Epilepsia* 2010. 51: 1069–1077 .

Lamberink HJ, Otte WM, Blümcke I, Braun KPJ, Aichholzer M, Amorim I, Aparicio J, Aronica E, Arzimanoglou A, Barba C, Beck J, Becker A, Beckervordersandforth JC, Bien CG, Blümcke I, Bodi I, Braun KP, Catenoix H, Chassoux F, Chipaux M, Cloppenborg T, Coras R, Cross JH, de Palma L, de Tisi J, Deleo F, Devaux B, di Genaro G, Dorfmüller G, Duncan JS, Elger C, Ernst K, Esposito V, Feucht M, Gadze ZP, Garbelli R, Geleijns K, Gil-Nagel A, Grote A, Grunwald T, Guerrini R, Hamer H, Honavar M, Jacques TS, Jakovcevic A, Jutila L, Kalina A, Kälviäinen R, Klein KM, Koenig K, Krsek P, Kudernatsch M, Kudr M, Lamberink HJ, Malmgren K, Marusic P, Melikyan A, Menzler K, Noachtar S, Otte WM, Özkara Ç, Pieper T, Pimentel J, Raicevic S, Rheims S, Ribeiro J, Rosenow F, Rössler K, Rydenhag B, Sales F, San Antonio-Arce V, Schaller KL, Schijns O, Scholl T, Schramm J, Schulze-Bonhage A, Sciort R, Seeck M, Shishkina L, Sokic D, Specchio N, Theys T, Thom M, Delgado RT, Toulouse J, Uzan M, van Loon J, van Paesschen W, von Oertzen TJ, Jansen F, Leijten F, van Rijen P, Spliet WG, Mühlebner A, Kasper BS, Fauser S, Polster T, Kalbhenn T, Delev D, McEvoy A, Misericocchi A, Landré E, Turak B, Varlet P, Ferrand-Sorbets S, Fohlen M, Bulteau C, Edelvik A, Shah MJ, Scheiwe C, Delicado EG, Tisdall M, Eltze C, Akkol S, Deniz K, Oz B, Holthausen H, Hartlieb T, Staudt M, Casciato S, Quarato PP, Giangaspero F, Streichenberger N, Guenot M, Isnard J, Valentijn A, Chang A, Mullatti N, Zamecnik J, Zarubova J, Tomasek M, Immonen A, Saarela A, Rauramaa T, Lobrinus JA, Egervari K, Momjian S, Harti E, Lohr H, Kroell J, Vermeulen L, Cleeren E, Vlasov P, Kozlova A, Vorobyev A, Goepfel G, Samueli S, Czech T, Hainfellner J, Puttinger G, Schwarz G, Stefanits H, Weis S, Spreafico R, Villani F, Rossini L, Hermsen A, Knake S, Nimsky C, Carl B, Belohlavkova A, Benova B, Bisschop J, Colon A, van Kranen-Mastenbroek V, Rouhl RP, Hoogland G, Rumiá J, Ramírez-Camacho A, Candela-Cantó S, Ostrowsky-Coste K, Panagiotakaki E, Montavont A, Kosal PK, Gokce-Samar Z, Milleret C, Buccoliero AM, Giordano F, Sulentic V, Mrak G, Desnica A, CarfiPavia G, de Benedictis A, Marras CE, Bascarevic V, Vojvodic N, Ristic A, Rebelo O, Aledo-Serrano A, Garcia-Morales I, Anciones C. Seizure outcome and use of antiepileptic drugs after epilepsy surgery according to histopathological diagnosis: a retrospective multicentre cohort study. *The Lancet Neurology* 2020. 19: 748–757 .



- Langfitt JT, Wiebe S. Early surgical treatment for epilepsy. *Current opinion in neurology* 2008. 21: 179–83 .
- Lee TMC, Yip JTH, Jones-Gotman M. Memory deficits after resection from left or right anterior temporal lobe in humans: a meta-analytic review. *Epilepsia* 2002. 43: 283–291 .
- Leon-Rojas JE, Iqbal S, Vos SB, Rodionov R, Miserocchi A, McEvoy AW, Vakharia VN, Mancini L, Galovic M, Sparks RE, Ourselin S, Cardoso JM, Koepp MJ, Duncan JS. Resection of the piriform cortex for temporal lobe epilepsy: a Novel approach on imaging segmentation and surgical application. *British Journal of Neurosurgery* 2021.
- Loring DW. Neuropsychological evaluation in epilepsy surgery. *Epilepsia* 1997. 38 Suppl 4: S18-23 .
- Lunney M, Wahby S, Sauro KM, Atkinson MJ, Josephson CB, Girgis F, Singh S, Patten SB, Jetté N, Sajobi TT, Hader W, Wiebe S. Patient satisfaction with epilepsy surgery: what is important to patients. *Epileptic Disorders* 2018. 20: 364–373 .
- Lutz MT, Clusmann H, Elger CE, Schramm J, Helmstaedter C. Neuropsychological Outcome after Selective Amygdalohippocampectomy with Transsylvian versus Transcortical Approach: A Randomized Prospective Clinical Trial of Surgery for Temporal Lobe Epilepsy. *Epilepsia* 2004. 45: 809–816 .
- McDonald CR, Busch RM, Reyes A, Arrotta K, Barr W, Block C, Hessen E, Loring DW, Drane DL, Hamberger MJ, Wilson SJ, Baxendale S, Hermann BP. Development and application of the International Classification of Cognitive Disorders in Epilepsy (IC-CoDE): Initial results from a multi-center study of adults with temporal lobe epilepsy. *Neuropsychology* 2022.
- Moscovitch M, Cabeza R, Winocur G, Nadel L. Episodic memory and beyond: The hippocampus and neocortex in transformation. *Annual Review of Psychology* 2016. 67: 105–134 .
- Mula M, Coleman H, Wilson SJ. Neuropsychiatric and cognitive comorbidities in epilepsy. *CONTINUUM Lifelong Learning in Neurology* 2022. 28: 457–482 .
- Perucca E, Berlowitz D, Birnbaum A, Cloyd JC, Garrard J, Hanlon JT, Levy RH, Pugh MJ. Pharmacological and clinical aspects of antiepileptic drug use in the elderly. *Epilepsy Research*. Elsevier, 49–63.

- Puka K, Tavares TP, Speechley KN. Social outcomes for adults with a history of childhood-onset epilepsy: A systematic review and meta-analysis. *Epilepsy & behavior : E&B* 2019. 92: 297–305 .
- Saling MM. Verbal memory in mesial temporal lobe epilepsy: beyond material specificity. *Brain : a journal of neurology* 2009. 132: 570–82 .
- Schramm J. Temporal lobe epilepsy surgery and the quest for optimal extent of resection: a review. *Epilepsia* 2008. 49: 1296–1307 .
- Scoville WB, Milner B. Loss of recent memory after bilateral hippocampal lesions. *Journal of neurology, neurosurgery, and psychiatry* 1957. 20: 11–21 .
- Sen A, Capelli V, Husain M. Cognition and dementia in older patients with epilepsy. *Brain : a journal of neurology* 2018. 141: 1592–1608 .
- Sherman EMS, Wiebe S, Fay-McClymont TB, Tellez-Zenteno J, Metcalfe A, Hernandez-Ronquillo L, Hader WJ, Jetté N. Neuropsychological outcomes after epilepsy surgery: systematic review and pooled estimates. *Epilepsia* 2011. 52: 857–69 .
- Tanriverdi T, Olivier A, Poulin N, Andermann F, Dubeau F. Long-term seizure outcome after mesial temporal lobe epilepsy surgery: cortical amygdalohippocampectomy versus selective amygdalohippocampectomy. *Journal of Neurosurgery JNS* 2008. 108: 517–524 .
- Taube J, Witt JA, Grote A, Delev D, Enkirch J, Hattingen E, Becker A, Elger C, Helmstaedter C. Preoperative and postoperative memory in epilepsy patients with 'gliosis only' versus hippocampal sclerosis: a matched case-control study. *Journal of Neurology, Neurosurgery, and Psychiatry* 2022.
- Tellez-Zenteno JF, Dhar R, Hernandez-Ronquillo L, Wiebe S. Long-term outcomes in epilepsy surgery: antiepileptic drugs, mortality, cognitive and psychosocial aspects. *Brain* 2007. 130: 334–345 .
- Trenerry MR. Neuropsychologic assessment in surgical treatment of epilepsy. *Mayo Clinic proceedings* 1996. 71: 1196–200 .
- Trenerry MR, Westerveld M, Meador KJ. MRI hippocampal volume and neuropsychology in epilepsy surgery. *Magnetic resonance imaging* 1995. 13: 1125–1132 .
- Vaughan DN, Jackson GD. The piriform cortex and human focal epilepsy. *Frontiers in neurology* 2014. 5: 259 .

- Vogt VL, Äikiä M, del Barrio A, Boon P, Borbély C, Bran E, Braun K, Carette E, Clark M, Cross JH, Dimova P, Fabo D, Foroglou N, Francione S, Gersamia A, Gil-Nagel A, Guekht A, Harrison S, Hecimovic H, Heminghyt E, Hirsch E, Javurkova A, Kälviäinen R, Kavan N, Kelemen A, Kimiskidis VK, Kirschner M, Kleitz C, Kobulashvili T, Kosmidis MH, Kurtish SY, Lesourd M, Ljunggren S, Lossius MI, Malmgren K, Mameniskienė R, Martin-Sanfilippo P, Marusic P, Miatton M, Özkara Ç, Pelle F, Rubboli G, Rudebeck S, Ryvlin P, van Schooneveld M, Schmid E, Schmidt PM, Seeck M, Steinhoff BJ, Shavel-Jessop S, Tarta-Arsene O, Trinkä E, Viggedal G, Wendling AS, Witt JA, Helmstaedter C. Current standards of neuropsychological assessment in epilepsy surgery centers across Europe. *Epilepsia* 2017. 58: 343–355 .
- Vogt VL, Witt JA, Malter MP, Schoene-Bake JC, von Lehe M, Elger CE, Helmstaedter C. Neuropsychological outcome after epilepsy surgery in patients with bilateral Ammon's horn sclerosis. *Journal of Neurosurgery* 2014. 121: 1247–1256 .
- Wiebe S, Blume WT, Girvin JP, Eliasziw M. A randomized, controlled trial of surgery for temporal-lobe epilepsy. *The New England journal of medicine* 2001. 345: 311–318 .
- Witt JA, Coras R, Schramm J, Becker AJ, Elger CE, Blümcke I, Helmstaedter C. The overall pathological status of the left hippocampus determines preoperative verbal memory performance in left mesial temporal lobe epilepsy. *Hippocampus* 2014a. 24: 446–454 .
- Witt JA, Helmstaedter C. Neuropsychologie bei epilepsie Teil II: Gibt es eine gemeinsame Basis zur etablierung diagnostischer leitlinien? *Fortschritte der Neurologie Psychiatrie* 2009. 77: 691–698 .
- Witt JA, Helmstaedter C. Should cognition be screened in new-onset epilepsies? A study in 247 untreated patients. *Journal of neurology* 2012. 259: 1727–1731 .
- Witt JA, Helmstaedter C. Cognition in the early stages of adult epilepsy. *Seizure* 2015. 26: 65–68 .
- Witt JA, Werhahn KJ, Krämer G, Ruckes C, Trinkä E, Helmstaedter C. Cognitive-behavioral screening in elderly patients with new-onset epilepsy before treatment. *Acta Neurologica Scandinavica* 2014b. 130: 172–177 .

Young JC, Vaughan DN, Nasser HM, Jackson GD. Anatomical imaging of the piriform cortex in epilepsy. *Experimental neurology* 2019. 320: 113013 .

Zannino GD, Murolo R, Grammaldo L, de Risi M, di Gennaro G, Esposito V, Caltagirone C, Carlesimo GA. Visuo-verbal distinction revisited: new insights from a study on temporal lobe epilepsy patients in the debate over the lateralization of material-specific and process-specific aspects of memory. *Journal of clinical and experimental neuropsychology* 2020. 42: 1085–1098 .

Zentner J, Wolf HK, Helmstaedter C, Grunwald T, Aliashkevich AF, Wiestler OD, Elger CE, Schramm J. Clinical relevance of amygdala sclerosis in temporal lobe epilepsy. *Journal of neurosurgery* 1999. 91: 59–67 .

## 6 Acknowledgements

An dieser Stelle möchte ich allen Menschen meinen großen Dank aussprechen, die mich bei der Anfertigung meiner Dissertation unterstützt haben.

Besonders danken möchte ich Christoph Helmstaedter und Juri-Alexander Witt für die hervorragende Betreuung bei der Umsetzung der gesamten Arbeit. Durch Ihr großes Engagement, fachliche Hinweise und Ihr professionelles Lektorat haben Sie wesentlich zum erfolgreichen Abschluss der Arbeit beigetragen.

Außerdem möchte ich Rene Hurlemann, Bernd Weber und Daniel Delev für die Begleitung meiner Doktorarbeit meinen Dank aussprechen.

Auch möchte ich Christian Hoppe, Carolin Meschede, Sophia Schach und Randi von Wrede meinen Dank aussprechen, die mich auf meinem Weg mit wertvollen Anregungen und lieben Worten begleitet haben.

Bei dieser Gelegenheit muss ich zudem den studentischen Hilfskräften der Neuropsychologie sowie den Kollegen und Kolleginnen der Klinik für Epileptologie Danke sagen, die meine Arbeit durch ihre Unterstützung beeinflusst haben.

Außerdem bedanke ich mich bei den Kollegen und Kolleginnen der Neurochirurgie, insbesondere Valeri Borger und Alexander Grote für die ausgezeichnete wissenschaftliche Zusammenarbeit.

Für die finanzielle und sachliche Unterstützung danke ich Christian Elger und Rainer Surges, die mich während meiner Dissertation als wissenschaftliche Mitarbeiterin an der Klinik für Epileptologie beschäftigt haben.

Mein besonderer Dank gilt meinen Großeltern, meinem Vater und meinen Freunden, die mich mit fortwährendem Zuspruch und viel Geduld während der Arbeit unterstützt haben.

## 7 Publications

1. Taube, J., Witt, J.-A., Grote, A., Delev, D., Enkirch, J., Hattingen, E., Becker, A. J., Elger, C. E., & Helmstaedter, C. (2022). Preoperative and postoperative memory in epilepsy patients with 'gliosis only' versus hippocampal sclerosis: a matched case–control study. In *Journal of Neurology, Neurosurgery & Psychiatry* (Vol. 93, Issue 11, pp. 1202–1208). BMJ. <https://doi.org/10.1136/jnnp-2022-329224>
2. Grote, A., Heiland, D.-H., Taube, J., Helmstaedter, C., Ravi, V. M., Will, P., Hattingen, E., Schüre, J.-R., Witt, J.-A., Reimers, A., Elger, C., Schramm, J., Becker, A. J., & Delev, D. (2022). 'Hippocampal innate inflammatory gliosis only' in pharmacoresistant temporal lobe epilepsy. In *Brain* (Vol. 146, Issue 2, pp. 549–560). Oxford University Press (OUP). <https://doi.org/10.1093/brain/awac293>
3. Taube, J., Witt, J.-A., Baumgartner, T., & Helmstaedter, C. (2022). All's well that ends well? Long-term course of a patient with anti-amphiphysin associated limbic encephalitis. In *Epilepsy&Behavior Reports* (Vol. 18, p. 100534). Elsevier BV. <https://doi.org/10.1016/j.ebr.2022.100534>
4. Borger, V., Hamed, M., Taube, J., Aydin, G., Ilic, I., Schneider, M., Schuss, P., Güresir, E., Becker, A., Helmstaedter, C., Elger, C. E., & Vatter, H. (2021). Resective temporal lobe surgery in refractory temporal lobe epilepsy: prognostic factors of postoperative seizure outcome. In *Journal of Neurosurgery* (Vol. 135, Issue 3, pp. 760–769). Journal of Neurosurgery Publishing Group (JNSPG). <https://doi.org/10.3171/2020.7.jns20284>
5. Borger, V., Schneider, M., Taube, J., Potthoff, A., Keil, V. C., Hamed, M., Aydin, G., Ilic, I., Solymosi, L., Elger, C. E., Güresir, E., Fimmers, R., Schuss, P., Helmstaedter, C., Surges, R., & Vatter, H. (2020). Resection of piriform cortex predicts seizure freedom in temporal lobe epilepsy. In *Annals of Clinical and Translational Neurology* (Vol. 8, Issue 1, pp. 177–189). Wiley. <https://doi.org/10.1002/acn3.51263>
6. Nass\*, R. D., Taube\*, J., Bauer, T., Rüber, T., Surges, R., & Helmstaedter, C. (2021). Permanent loss of independence in adult febrile-infection-related epilepsy syndrome survivors: an underestimated and unsolved challenge. In *European Journal of Neurology* (Vol. 28, Issue 9, pp. 3061–3071). Wiley. <https://doi.org/10.1111/ene.14958>
7. Delev, D., Taube, J., Helmstaedter, C., Hakvoort, K., Grote, A., Clusmann, H., & Lehe, M. von. (2020). Surgery for temporal lobe epilepsy in the elderly: Improving quality of life despite cognitive impairment. In *Seizure* (Vol. 79, pp. 112–119). Elsevier BV. <https://doi.org/10.1016/j.seizure.2020.05.003>
8. Seyer, F., Witt, J.-A., Taube, J., & Helmstaedter, C. (2018). The efficacy of a short-term multidisciplinary epilepsy program. In *Epilepsy & Behavior* (Vol. 86, pp. 98–101). Elsevier BV. <https://doi.org/10.1016/j.yebeh.2018.06.017>
9. Taube J, Witt JA, Helmstaedter C. (2017). Neuropsychologische Diagnostik bei Epilepsie: Fortschritte und aktuelle Entwicklungen. *Zeitschrift für Epileptologie*; 31(Pt. 4).